DEVELOPMENT OF HUMAN EYE AND ASSOCIATED STRUCTURES

Prof Peter Gichangi

February 2017

OBJECTIVES

- Understand development of the eye and related structures
- Understand eye related congenital malformation

- Early eye development results from a series of inductive signals.
- The eyes are derived from four sources:
  - The neuroectoderm of the forebrain
  - The surface ectoderm of the head
  - The mesoderm between the above layers
  - Neural crest cells
- The **neuroectoderm** of the forebrain differentiates into the:
  - retina,
  - the posterior layers of the iris,
  - optic nerve.
- The **surface ectoderm** forms:
  - the lens of the eye
  - the corneal epithelium.

- The **mesoderm** between the neuroectoderm and surface ectoderm gives rise to the:
  - Fibrous tissue
  - vascular coats of the eye.
- **Neural crest** differentiate into:
  - the choroid,
  - sclera,
  - corneal endothelium
- Homeobox-containing genes, including the transcription regulator Pax6, fibroblast growth factors, and other inducing factors play an important role in the molecular development of the eye.

- Eye development is first evident at the beginning of the **fourth week**.

Events:

- Appearance of **Optic grooves** (*sulci*) in the neural folds at the cranial end of the embryo.
- Evagination of the optic grooves to form hollow diverticula - **optic vesicles** - that project from the wall of the forebrain into the adjacent mesenchyme.
  - The cavities of the optic vesicles are continuous with the cavity of the forebrain.
- Formation of hollow **optic stalks** by constriction of the connection with forebrain and expansion of the distal ends of optic vesicle.

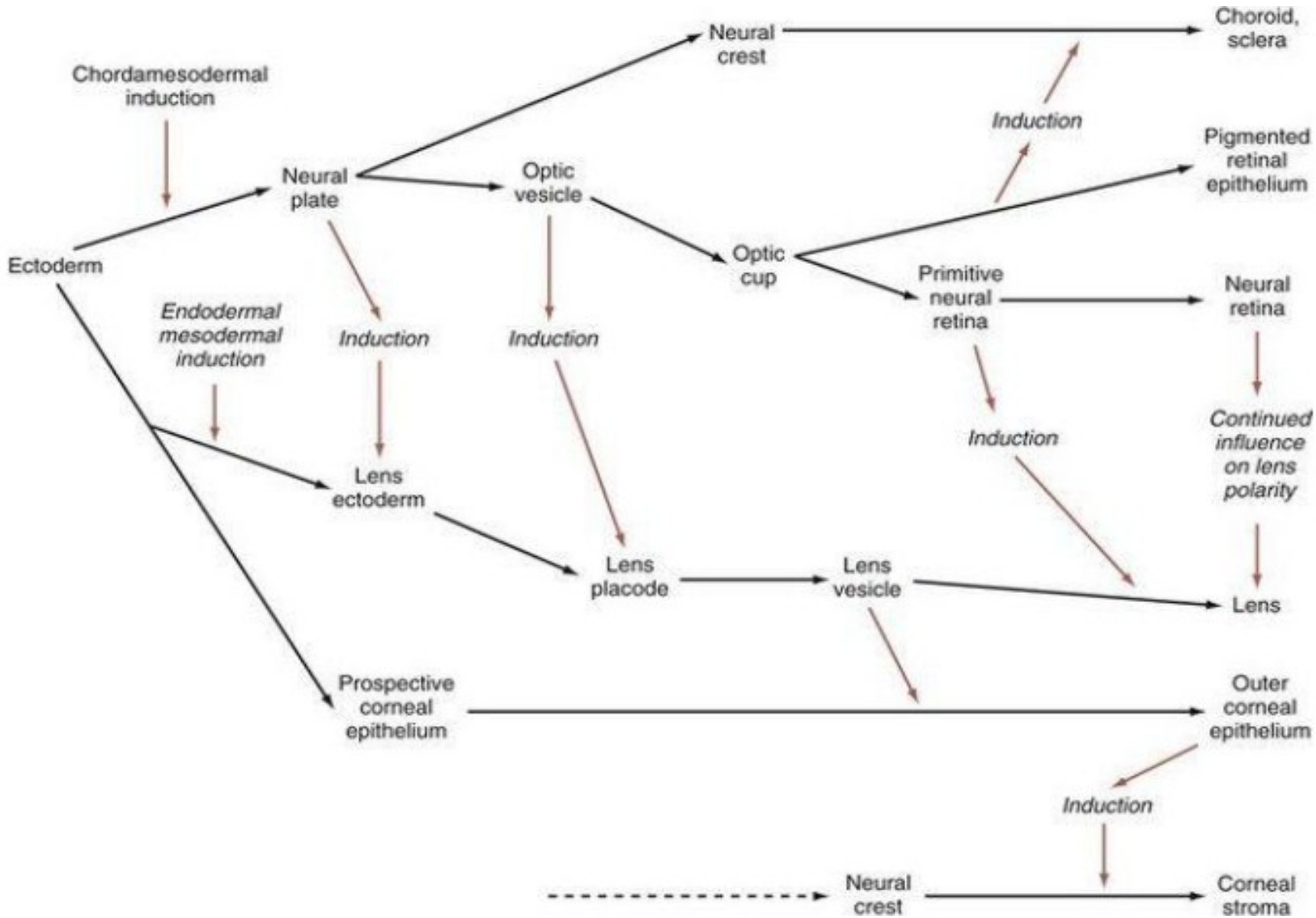

Inductive events are indicated by *colored arrows*

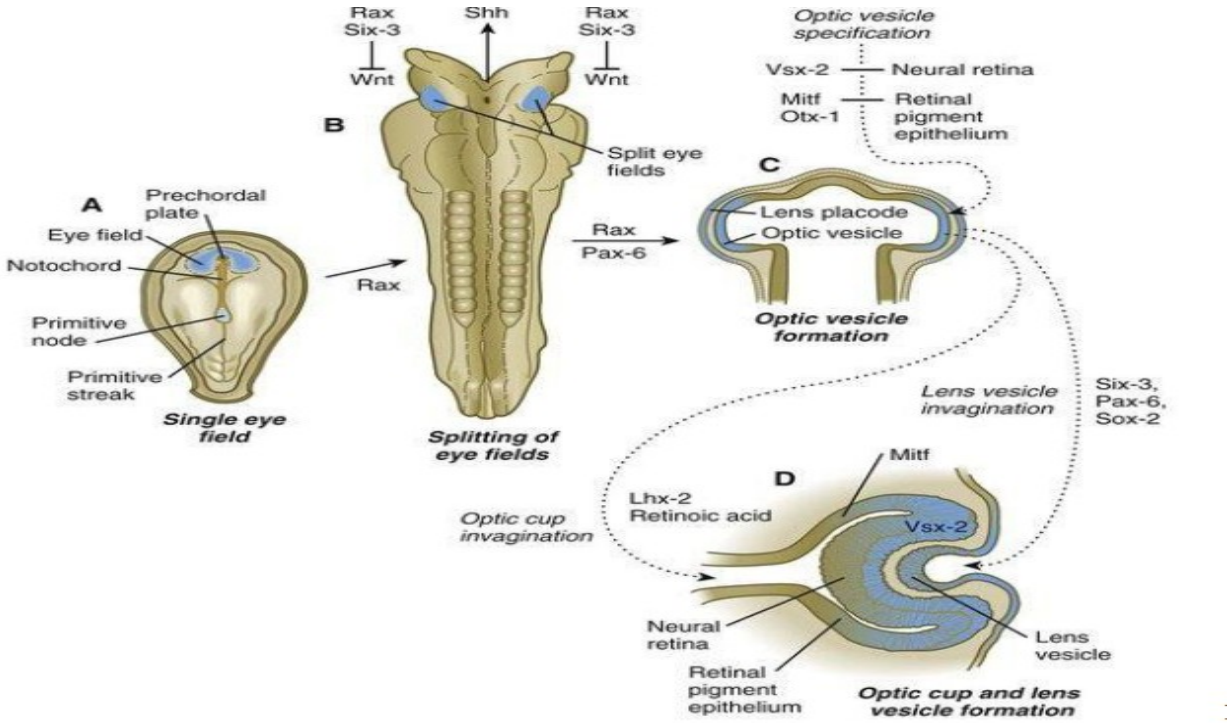

A, A single eye field forms during late gastrulation.
B, Through the action of sonic hedgehog (Shh), the single eye field splits into bilateral fields.
C, The formation of optic vesicles is heavily dependent on the expression of Pax-6 and Rax. The optic vesicles are patterned into future neural retina (through Vsx-2) and retinal pigment epithelium (through Mitf and Otx-2).
D, Inductive interactions between the optic vesicle and the overlying lens placode result in invagination of both the optic cup and the lens vesicle.

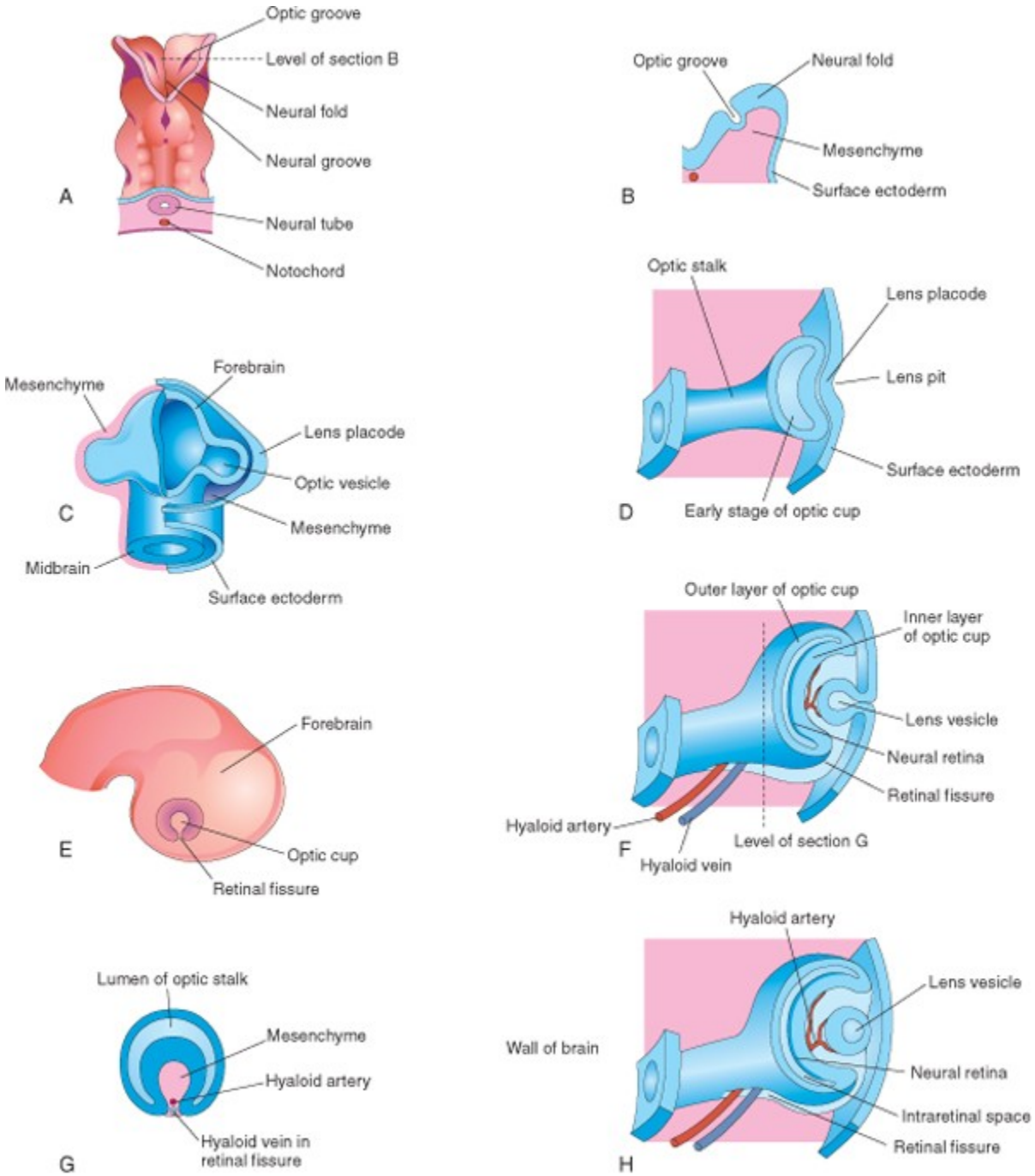

© Elsevier. Moore & Persaud: The Developing Human 8e - www.studentconsult.com

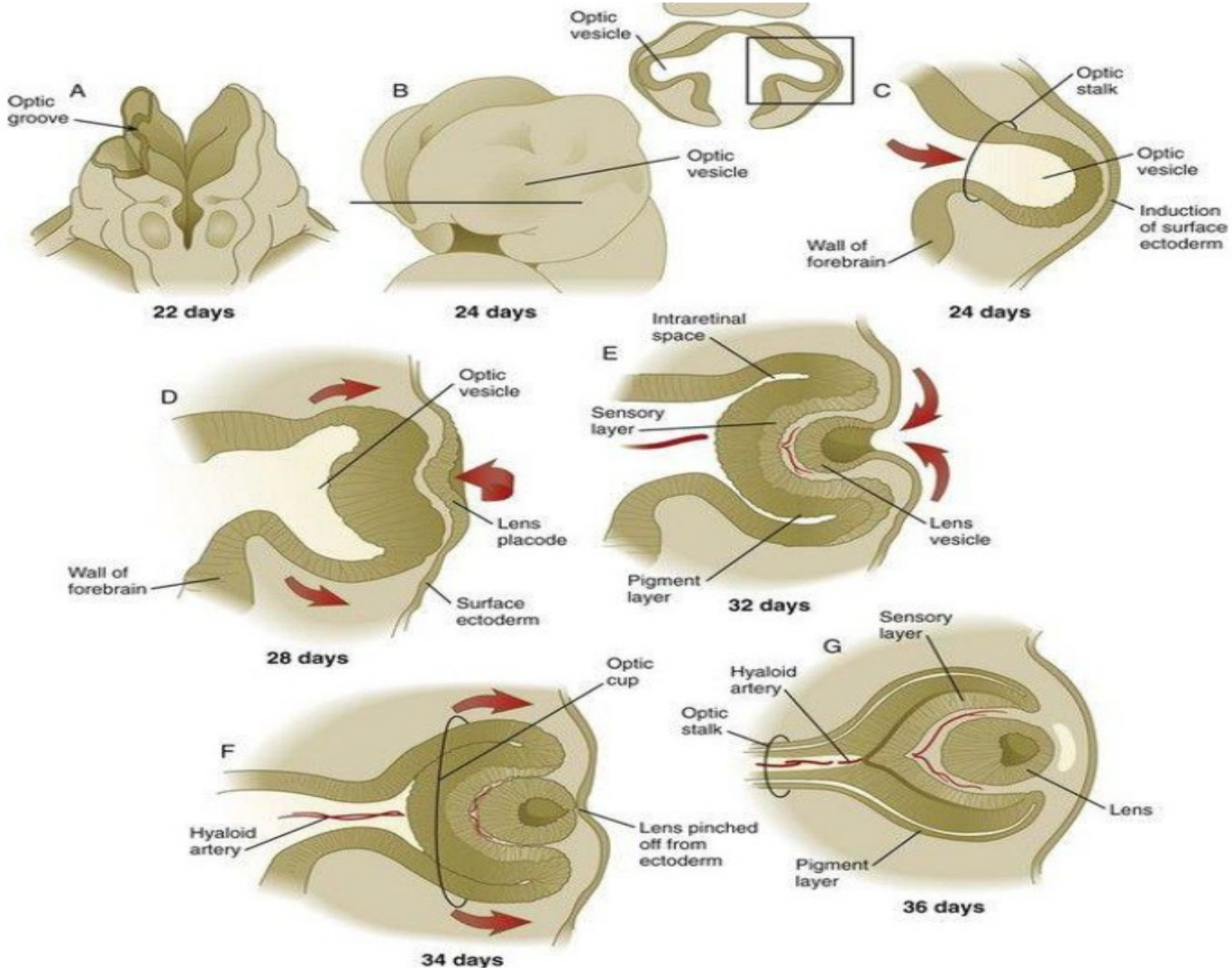

A to **G,** Early development of the human eye

- The optic vesicles as it grows makes contact with the surface ectoderm leading to its thickening to form **lens placodes**, the **lens primordia**.
- Formation of lens placodes is induced by the optic vesicles.
- The lens placodes invaginate to form **lens pits**.
- The edges of the pits approach each other and fuse to form spherical **lens vesicles**, which soon lose their connection with the surface ectoderm.

- As the lens vesicles are developing, the optic vesicles invaginate to form double-walled **optic cups**.
- The opening of each cup is large at first, but its rim infolds around the lens.
- The lens vesicles lose their connection with the surface ectoderm and enter the cavities of the optic cups.
- **Retinal fissures** (optic fissures) develop on the ventral surface of the optic cups and along the optic stalk.
  - The fissures contain vascular mesenchyme from which the hyaloid blood vessels develop.
- The **hyaloid artery**, a branch of the ophthalmic artery, supplies the inner layer of the optic cup, the lens vesicle, and the mesenchyme in the **cavity of the optic cup**.
- The **hyaloid vein** returns blood from these structures.
- As the edges of the retinal fissure fuse, the hyaloid vessels are enclosed within the **primordial optic nerve**.
- Distal parts of the hyaloid vessels eventually degenerate, but proximal parts persist as the **central artery** and **vein of the retina**.

© Elsevier. Moore & Persaud: The Developing Human 8e - www.studentconsult.com

© Elsevier. Moore & Persaud: The Developing Human 8e - www.studentconsult.com

Photomicrograph of a sagittal section of the eye of an embryo (×100) at Carnegie stage 18, approximately 44 days. Observe that it is the posterior wall of the lens vesicle that forms the lens fibers. The anterior wall does not change appreciably as it becomes the anterior lens epithelium.

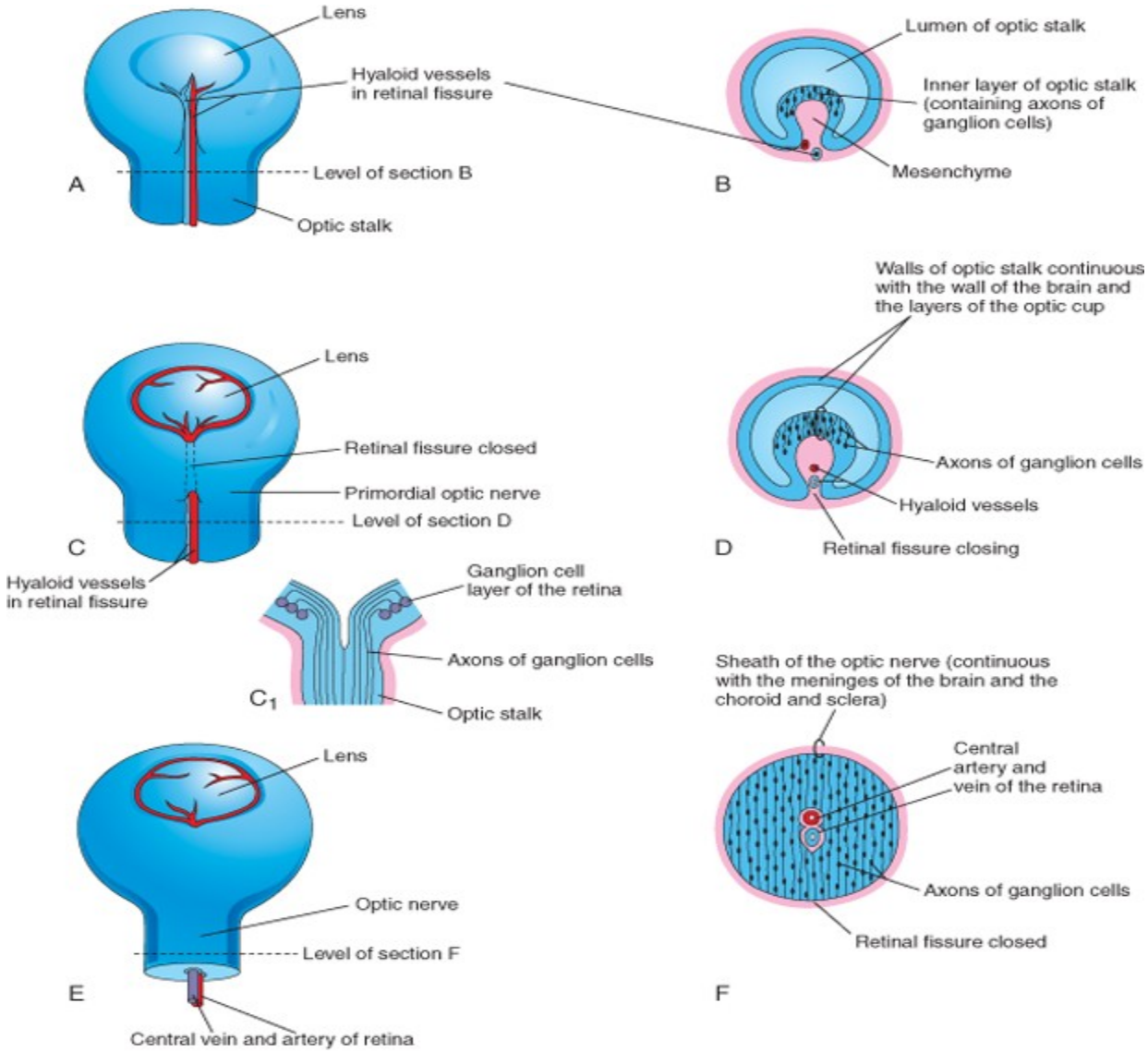

© Elsevier. Moore & Persaud: The Developing Human 8e - www.studentconsult.com

Illustrations of the closure of the retinal fissure and formation of the optic nerve. A, C, and E, Views of the inferior surface of the optic cup and stalk showing progressive stages in the closure of the retinal fissure. C1, Schematic sketch of a longitudinal section of a part of the optic cup and stalk showing axons of ganglion cells of the retina growing through the optic stalk to the brain. B, D, and F, Transverse sections of the optic stalk showing successive stages in closure of the retinal fissure and formation of the optic nerve. The retinal fissure normally closes during the sixth week. Defects in closure of the fissure result in coloboma of the iris and/or retina. Note that the lumen of the optic stalk is gradually obliterated as axons of ganglion cells accumulate in the inner layer of the optic stalk as the optic nerve forms.

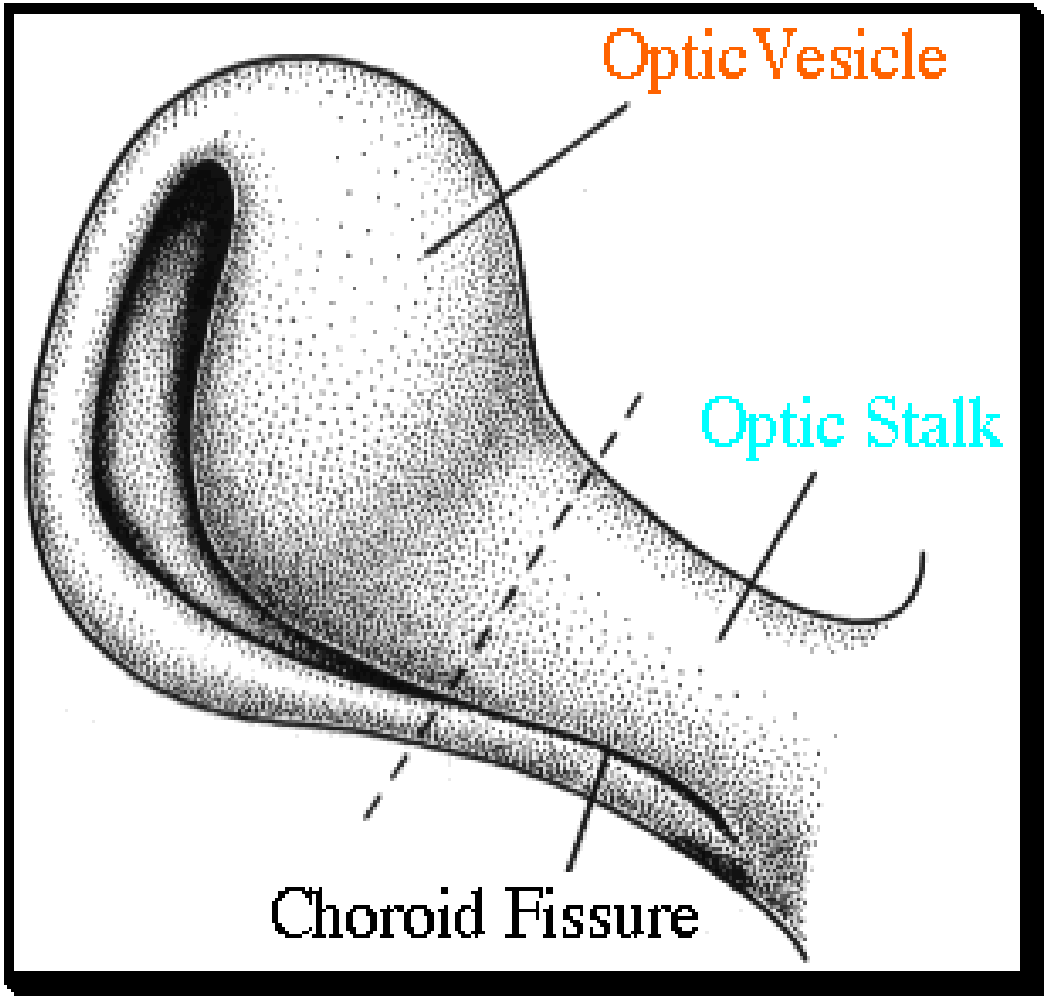

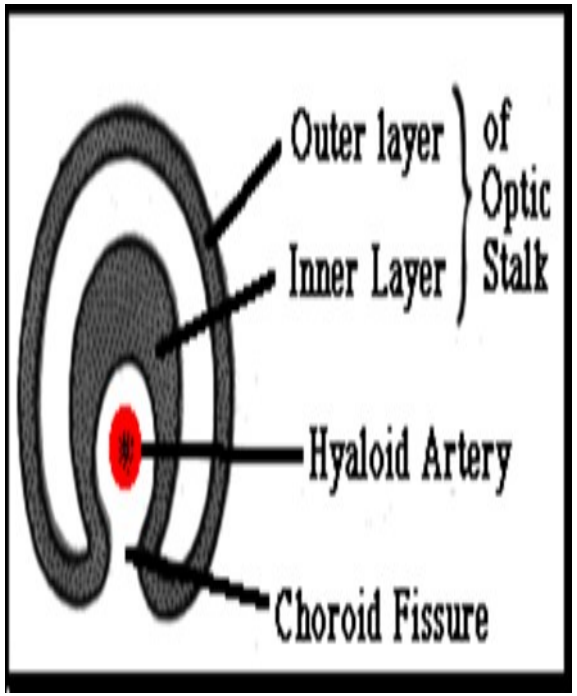

The optic vesicle and the optic stalk invaginate, forming the choroid fissure inferiorly.

DEVELOPMENT OF THE RETINA

- The retina develops from the walls of the *optic cup*, an outgrowth of the forebrain.
  - The outer, thinner layer of the optic cup becomes the retinal pigment epithelium (**pigmented layer of retina**),
  - The inner, thicker layer differentiates into the neural retina (**neural layer of retina**).
- During the embryonic and early fetal periods, the two retinal layers are separated by an **intraretinal space**, which is the original cavity of the optic cup.

© Elsevier. Moore & Persaud: The Developing Human 8e - www.studentconsult.com

- Before birth, intraretinal space gradually disappears as the two layers of the retina fuse, but this fusion is not firm - can separate neural layer from the pigment layer.
- Layers of the optic cup are continuous with the wall of the brain-out growth of forebrain.
- Under the influence of the developing lens, the inner layer of the optic cup proliferates to form a thick **neuroepithelium**.
- **Neuroepithelium** cells differentiate into the **neural retina**.

© Elsevier. Moore & Persaud: The Developing Human 8e - www.studentconsult.com

Photomicrograph of a sagittal section of the eye of an embryo (×100) at Carnegie stage 18, approximately 44 days. Observe that it is the posterior wall of the lens vesicle that forms the lens fibers. The anterior wall does not change appreciably as it becomes the anterior lens epithelium.

Tissue and cellular organiza tion of the neural retina of a human fetus

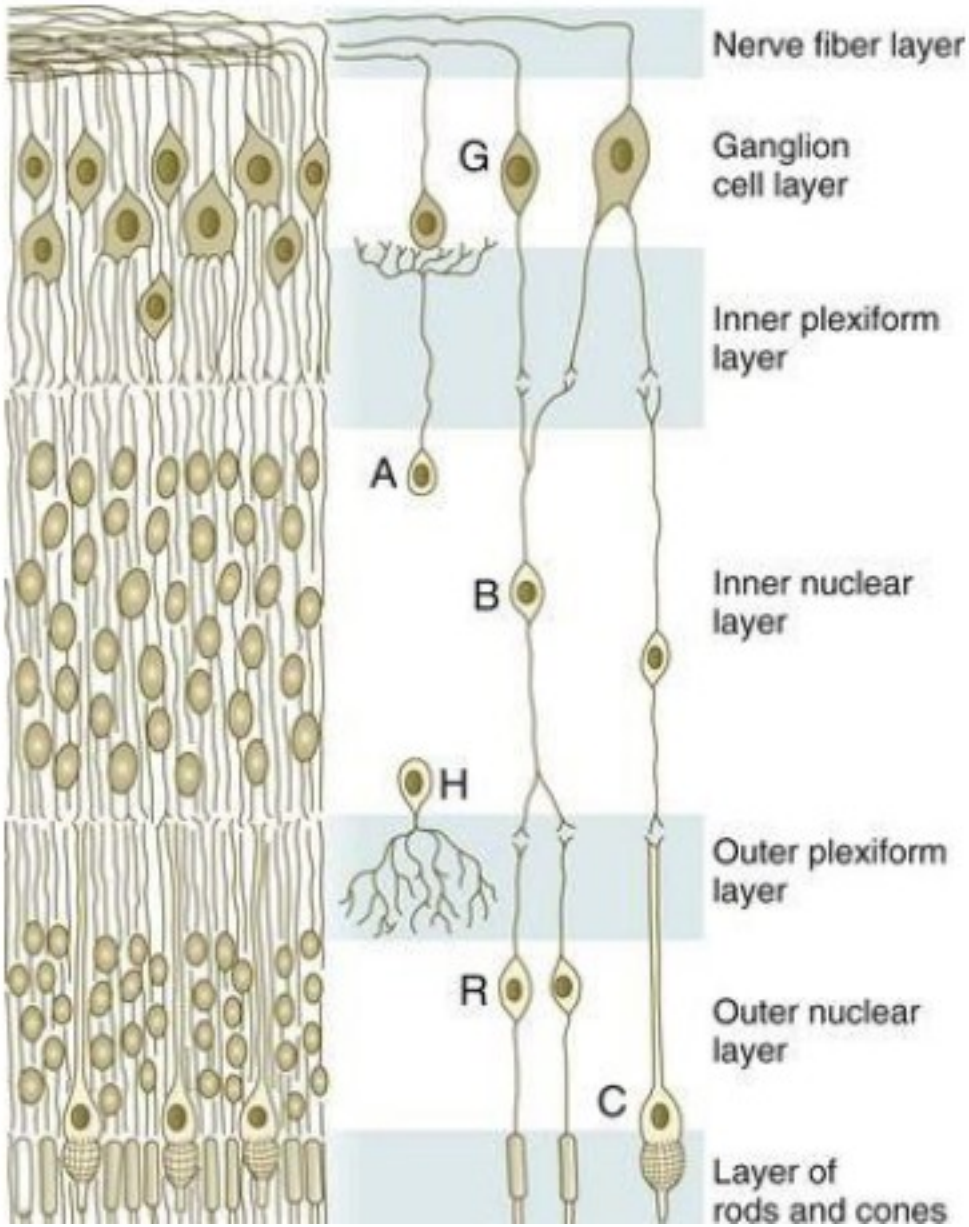

A, Molecular basis for the specification of pattern of the neural retina. The original molecular drivers are sonic hedgehog (Shh) ventrally and bone morphogenetic protein-4 (BMP-4) dorsally. The molecular interactions indicated by the *arrows* are supplemented by dorsoventral and nasotemporal gradients of ephrins and their receptors. **B,** Horizontal and vertical gradients in the differentiation of the layers of the neural retina

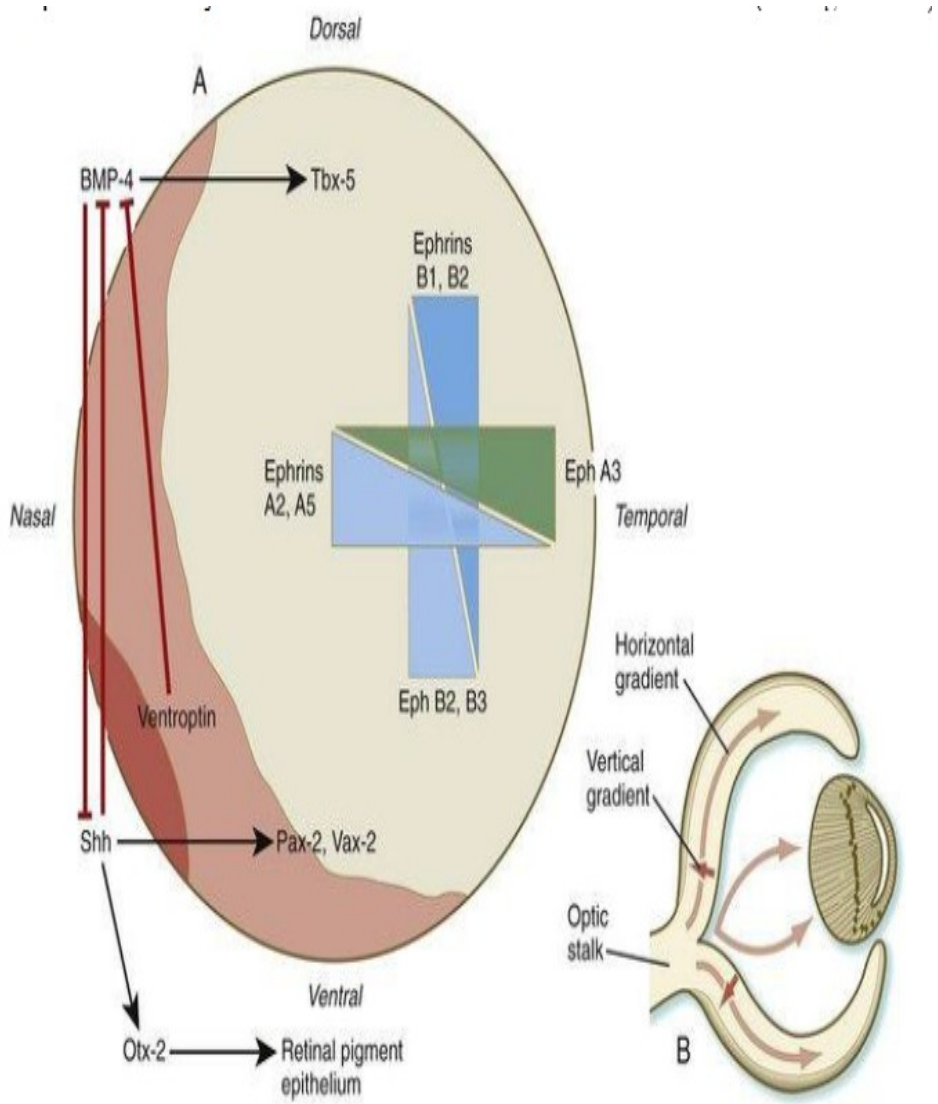

- Neural retina contains photoreceptors (rods and cones) and the cell bodies of neurons (e.g., bipolar and ganglion cells).
  - Retinal ganglion cell differentiation is signaled/regulated by Fibroblast growth factor.
- Because the optic vesicle invaginates as it forms the optic cup, the neural retina is "inverted," that is, light-sensitive parts of the photoreceptor cells are adjacent to the retinal pigment epithelium.
- Light must pass through the thickest part of the retina before reaching the receptors.
- However, because the retina overall is thin and transparent, it does not form a barrier to light.
- The axons of ganglion cells in the superficial layer of the neural retina grow proximally in the wall of the **optic stalk** to the brain.
- As a result, the cavity of the optic stalk is gradually obliterated as the axons of the many ganglion cells form the **optic nerve**.

- Myelination of optic nerve fibers is incomplete at birth.
- After the eyes have been exposed to light for approximately 10 weeks, myelination is complete, but the process normally stops short of the optic disc, where the optic nerve enters the eyeball.
- Normal newborn infants can see, but not too well; they respond to changes in illumination and are able to fixate points of contrast.
  - Visual acuity has been estimated to be in the range of 20/400.
- At 2 weeks of age, the infants show a more sustained interest in large objects.

CONGENITAL DETACHMENT OF THE RETINA

- Congenital detachment of the retina occurs when the inner and outer layers of the optic cup fail to fuse during the fetal period to obliterate the intraretinal space - primary detachment.
- Detachment may be partial or complete.
- Retinal detachment may result from unequal rates of growth of the two retinal layers; as a result, the layers of the optic cup are not in perfect apposition.
- Secondary detachments usually occur in association with other anomalies of the eye and head.

- Although separated from the retinal pigment epithelium, the neural retina retains its blood supply (central artery of retina), derived from the embryonic hyaloid artery.
- Detached retina may follow a blow to the eyeball, as may occur during a boxing match.
  - As a result, fluid accumulates between the layers and vision is impaired.

EDEMA OF THE OPTIC DISC

- The optic nerve is surrounded by three sheaths that evaginated with the optic vesicle and stalk; which are continuous with the meninges of the brain.
  - The outer dural sheath from the dura mater is thick and fibrous and blends with the sclera.
  - The intermediate sheath from the arachnoid mater is thin.
  - The inner sheath from the pia mater is vascular and closely invests the optic nerve and central vessels of the retina as far as the optic disc.
  - Cerebrospinal fluid is present in the subarachnoid space between the intermediate and inner sheaths of the optic nerve.

- The relationship of the sheaths of the optic nerve to the meninges of the brain and the subarachnoid space is important clinically.
- An increase in CSF pressure (often resulting from increased intracranial pressure) slows venous return from the retina, causing **papilledema** (fluid accumulation) of the optic disc.
- This occurs because the retinal vessels are covered by pia mater and lie in the extension of the subarachnoid space that surrounds the optic nerve.

DEVELOPMENT OF THE CILIARY BODY

- The ciliary body is a wedge-shaped extension of the choroid.
- Its medial surface projects toward the lens, forming **ciliary processes**.
- The **pigmented** portion of the ciliary epithelium is derived from the outer layer of the optic cup and is continuous with the retinal pigment epithelium.
- The **nonpigmented** portion of the ciliary epithelium represents the anterior prolongation of the neural retina in which **no neural elements develop.**
- The **ciliary muscle**-the smooth muscle of the ciliary body that is responsible for focusing the lens-and the connective tissue in the ciliary body develop from mesenchyme located at the edge of the optic cup in the region between the anterior scleral condensation and the ciliary pigment epithelium.

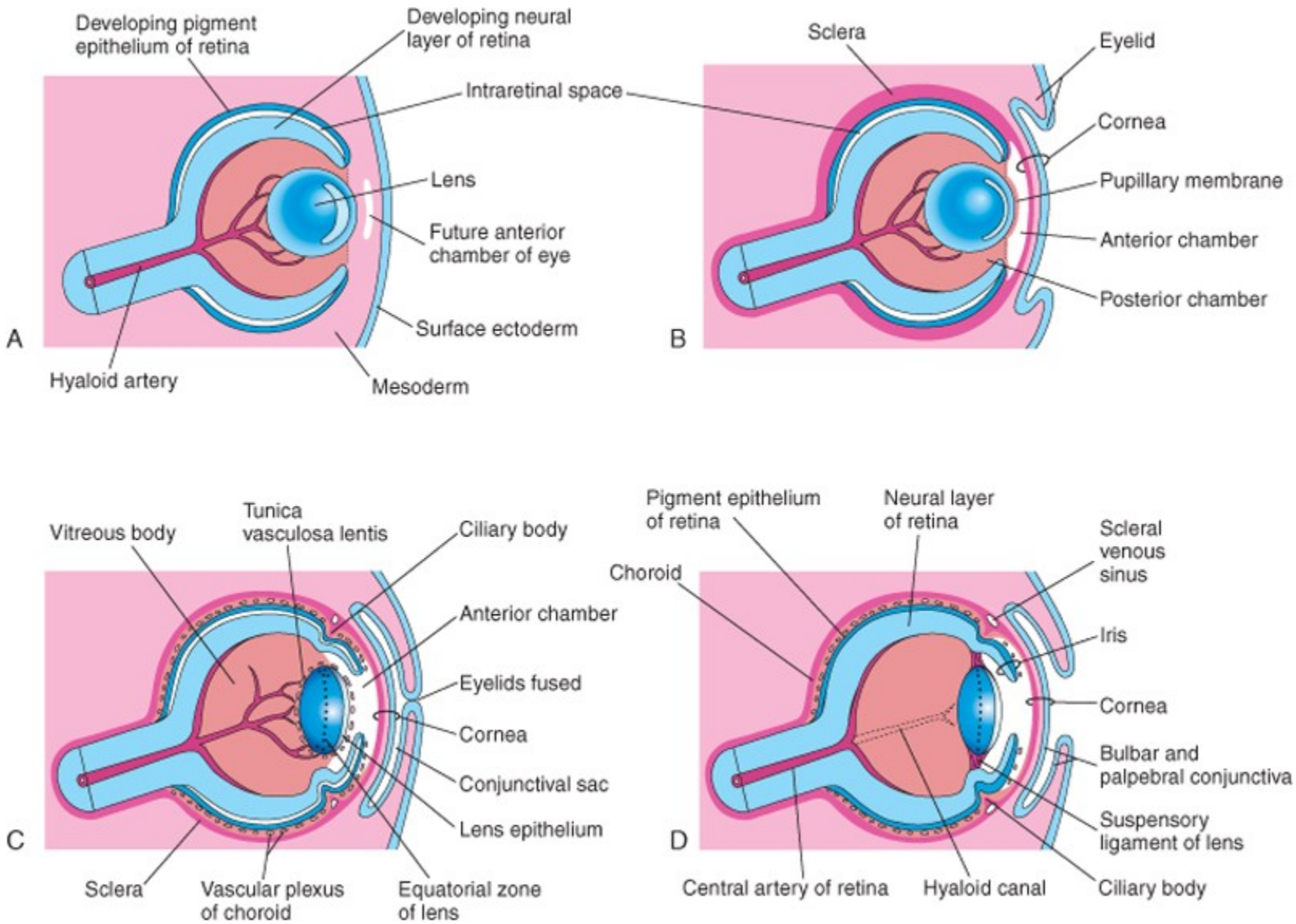

© Elsevier. Moore & Persaud: The Developing Human 8e - www.studentconsult.com

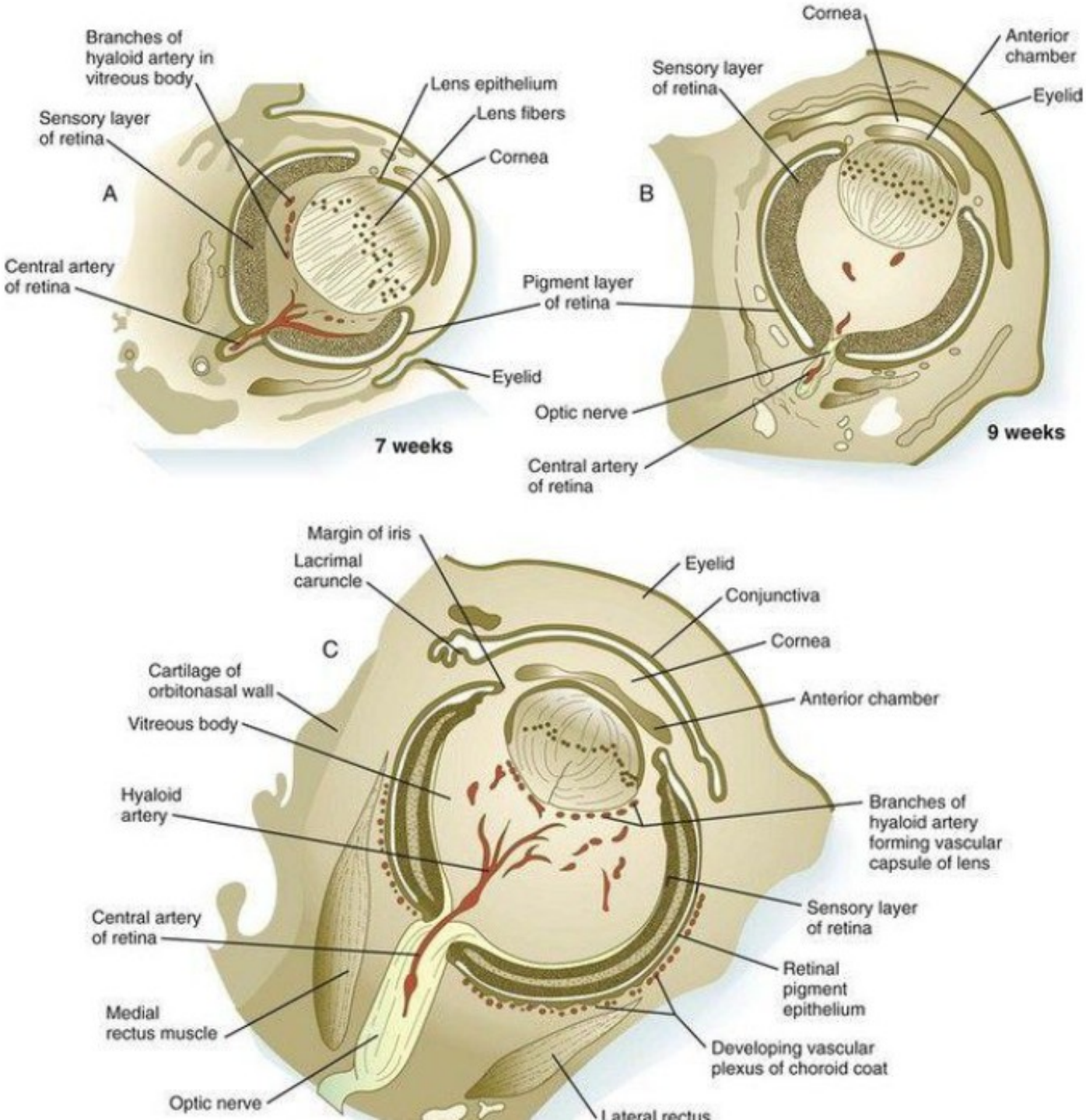
Branches of hyaloid artery in vitreous body
Sensory layer of retina
Lens epithelium
Lens fibers
Cornea
A
Central artery of retina
Pigment layer of retina
Eyelid
7 weeks
Cornea
Anterior chamber
Sensory layer of retina
Eyelid
B
Optic nerve
Central artery of retina
9 weeks
Margin of iris
Lacrimal caruncle
Eyelid
Conjunctiva
Cornea
C
Cartilage of orbitonasal wall
Anterior chamber
Vitreous body
Hyaloid artery
Branches of hyaloid artery forming vascular capsule of lens
Sensory layer of retina
Central artery of retina
Retinal pigment epithelium
Medial rectus muscle
Developing vascular plexus of choroid coat
Optic nerve
Lateral rectus

DEVELOPMENT OF THE IRIS

- The iris develops from the rim of the optic cup, which grows inward and partially covers the lens.
- The two layers of the optic cup remain thin in this area.
- The epithelium of the iris represents both layers of the optic cup; it is continuous with the double-layered epithelium of the ciliary body and with the retinal pigment epithelium and neural retina.
- The connective tissue framework (stroma) of the iris is derived from **neural crest cells** that migrate into the iris.
- The **dilator pupillae** and **sphincter pupillae** muscles of the iris are derived from **neuroectoderm of the optic cup**.
- They appear to arise from the anterior epithelial cells of the iris.
- **These smooth muscles result from a transformation of epithelial cells into smooth muscle cells.**

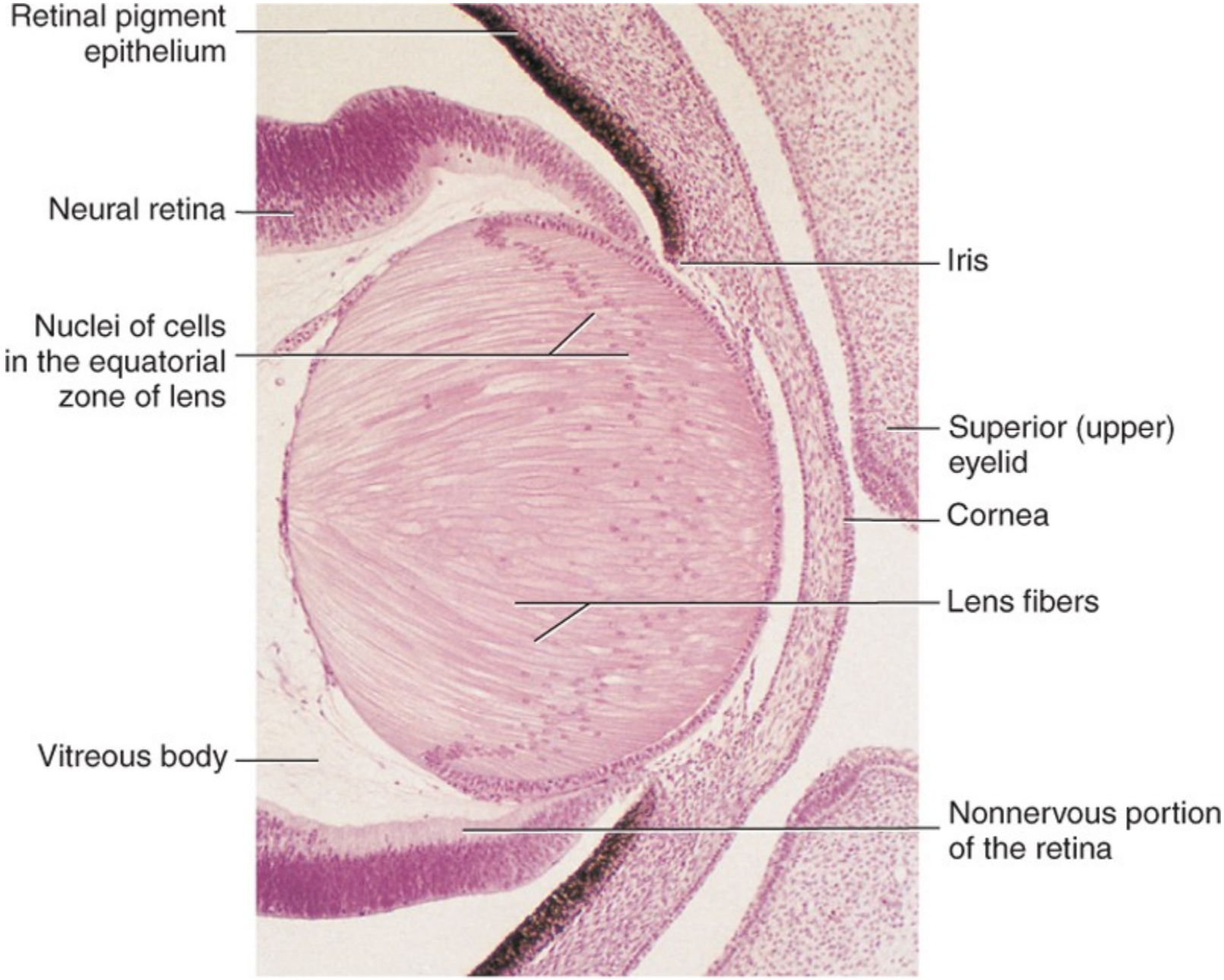

© Elsevier. Moore & Persaud: The Developing Human 8e - www.studentconsult.com

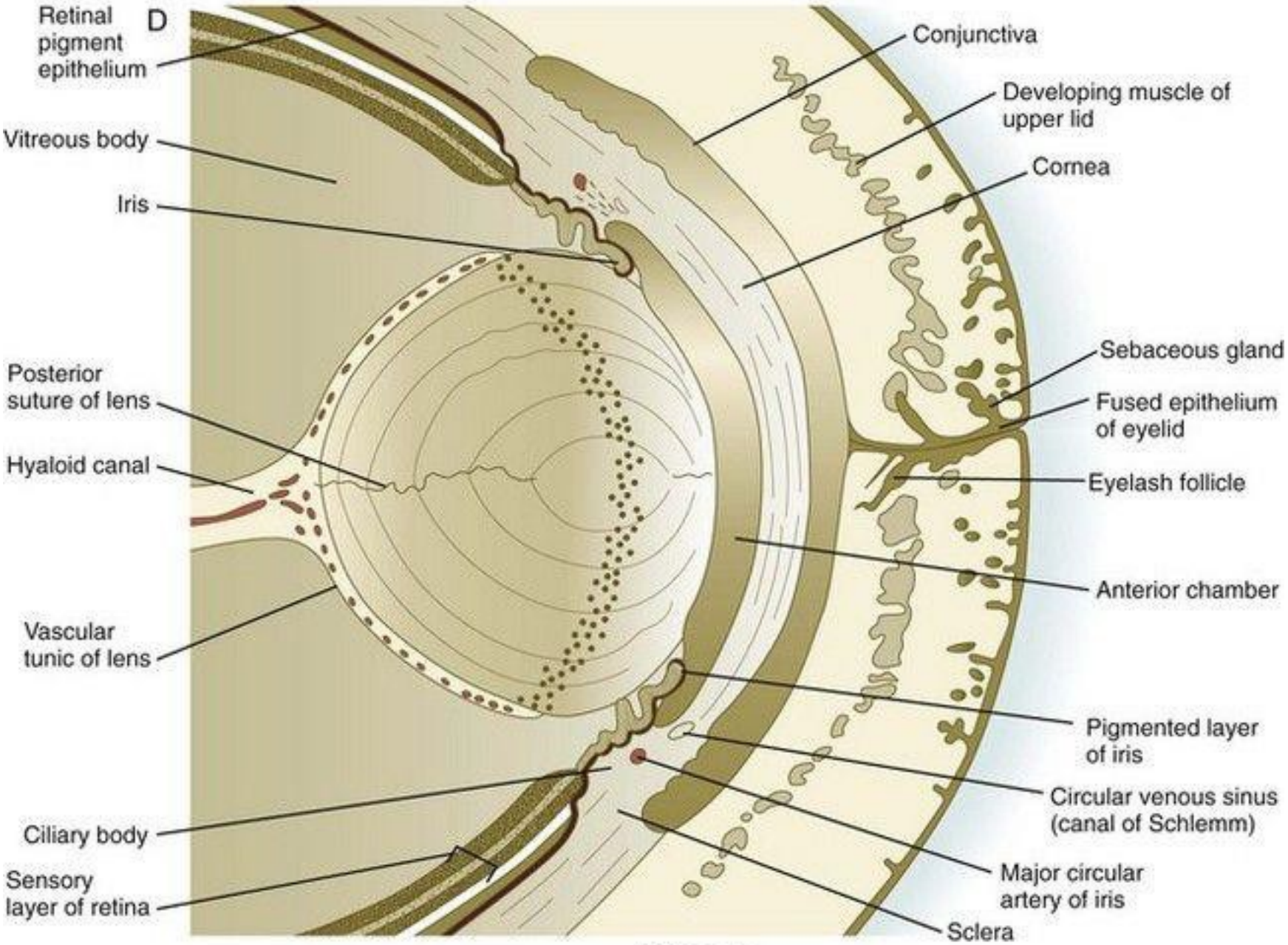
D
Retinal pigment epithelium
Vitreous body
Iris
Posterior suture of lens
Hyaloid canal
Vascular tunic of lens
Ciliary body
Sensory layer of retina
Conjunctiva
Developing muscle of upper lid
Cornea
Sebaceous gland
Fused epithelium of eyelid
Eyelash follicle
Anterior chamber
Pigmented layer of iris
Circular venous sinus (canal of Schlemm)
Major circular artery of iris
Sclera

19 weeks

COLOR OF THE IRIS

- The iris is typically light blue or gray in most newborn infants.
- The iris acquires its definitive color as pigmentation occurs during the first 6 to 10 months.
- The concentration and distribution of pigment-containing cells-**chromatophores**-in the loose vascular connective tissue of the iris determine eye color.
  - If the melanin pigment is confined to the pigmented epithelium on the posterior surface of the iris, the iris appears blue.
  - If melanin is also distributed throughout the stroma (supporting tissue) of the iris, the eye appears brown.

CONGENITAL ANIRIDIA

- In this rare anomaly, there is almost complete absence of the iris.
- This defect results from an arrest of development at the rim of the optic cup during the eighth week.
- The anomaly may be associated with glaucoma and other eye abnormalities.
- Aniridia may be familial, the transmission being dominant or sporadic.
- In humans, mutation of the *Pax6* gene results in aniridia.

Heterochromia (also known as a heterochromia iridis or heterochromia iridium) is an ocular condition in which one iris is a different color from the other iris. The subject on the photo above has a brown and hazel eye.

Coloboma of the Iris

- Coloboma is a defect in the inferior sector of the iris or a notch in the pupillary margin, giving the pupil a keyhole appearance.
- The defect may be limited to the iris or it may extend deeper and involve the ciliary body and retina.
- *A typical coloboma of the iris results from failure of closure of the retinal fissure during the sixth week*.
- The defect may be caused by environmental factors.
- A simple coloboma is frequently hereditary and is transmitted as an autosomal dominant characteristic.

© Elsevier. Moore & Persaud: The Developing Human 8e - www.studentconsult.com

DEVELOPMENT OF THE LENS

- The lens develops from the **lens vesicle**, a derivative of the surface ectoderm.
- The anterior wall of this vesicle, composed of cuboidal epithelium, becomes the subcapsular **lens epithelium.**
- The nuclei of the tall columnar cells forming the posterior wall of the lens vesicle undergo dissolution.
  - These cells lengthen considerably to form highly transparent epithelial cells, the **primary lens fibers**.
- As these fibers grow, they gradually obliterate the cavity of the lens vesicle.

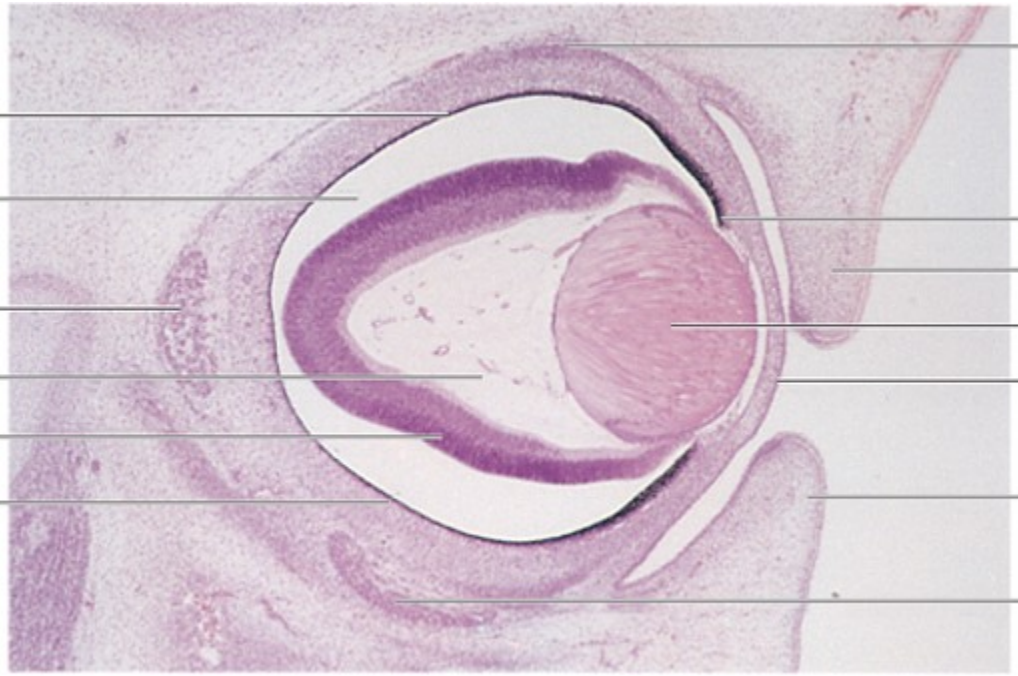

© Elsevier. Moore & Persaud: The Developing Human 8e - www.studentconsult.com

- The rim of the lens is known as the **equatorial zone** because it is located midway between the anterior and posterior poles of the lens.
- The cells in the equatorial zone are cuboidal; as they elongate, they lose their nuclei and become **secondary lens fibers**.
- These new lens fibers are added to the external sides of the primary lens fibers.
- Although secondary lens fibers continue to form during adulthood and the lens increases in diameter, the primary lens fibers must last a lifetime.

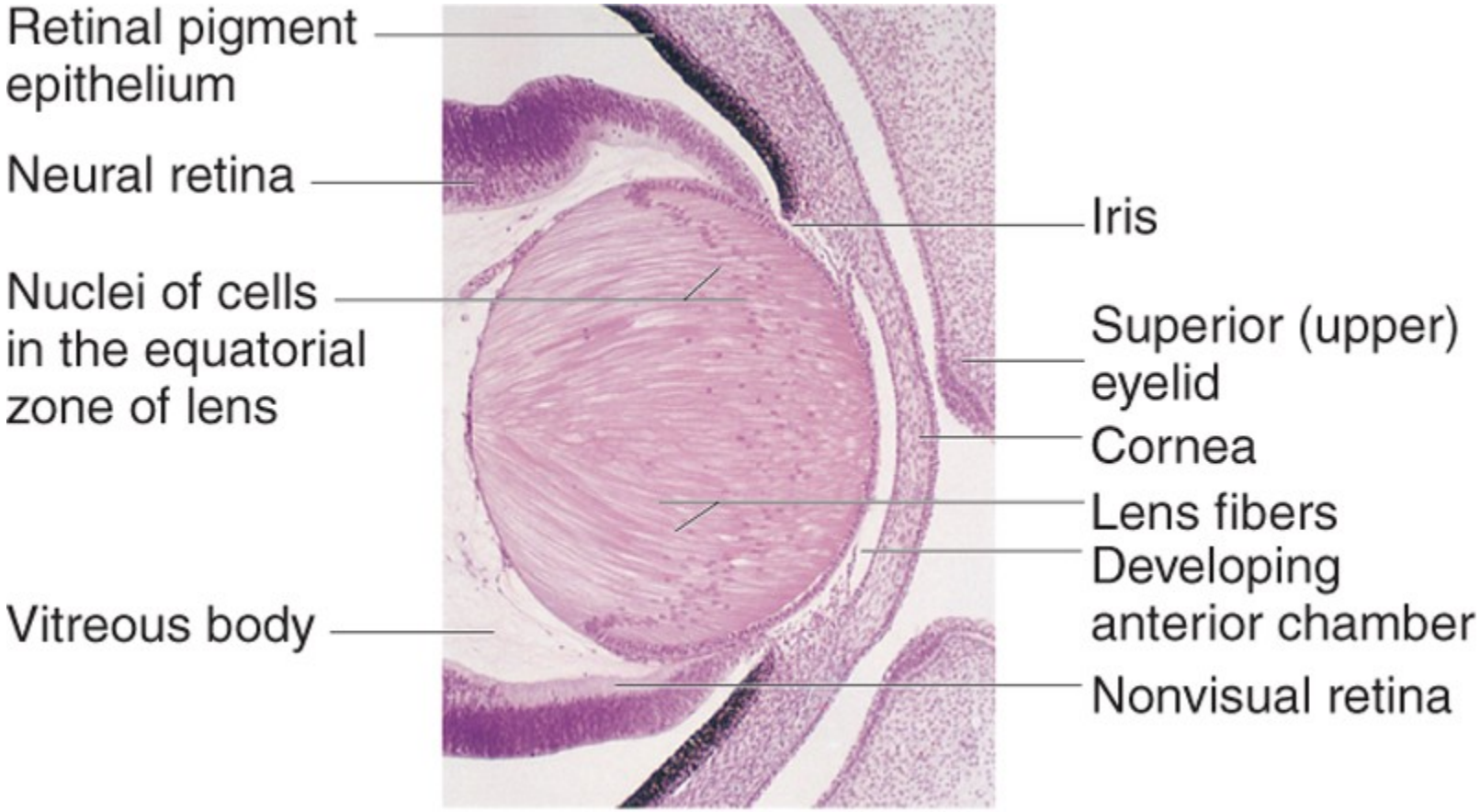

© Elsevier. Moore & Persaud: The Developing Human 8e - www.studentconsult.com

Photomicrograph of a portion of the developing eye. Observe that the lens fibers have elongated and obliterated the cavity of the lens vesicle. Note that the inner layer of the optic cup has thickened greatly to form the neural retina and that the outer layer is heavily pigmented (retinal pigment epithelium).

- Lens nutrition
- During development: distal part of the **hyaloid artery**;.
- Later nutrition when avascular: from the aqueous humor in the **posterior and anterior chamber of the eye**, and from the vitreous humor.
- The developing lens is invested by a vascular mesenchymal layer, the **tunica vasculosa lentis**.
- The anterior part of this capsule is the **pupillary membrane**.
- When hyaloid artery degenerate, the tunica vasculosa lentis and pupillary membrane degenerate.
- The **lens capsule** produced by the anterior lens epithelium and the lens fibers persists.
- The lens capsule represents a **greatly thickened basement membrane**.
- The former site of the hyaloid artery is indicated by

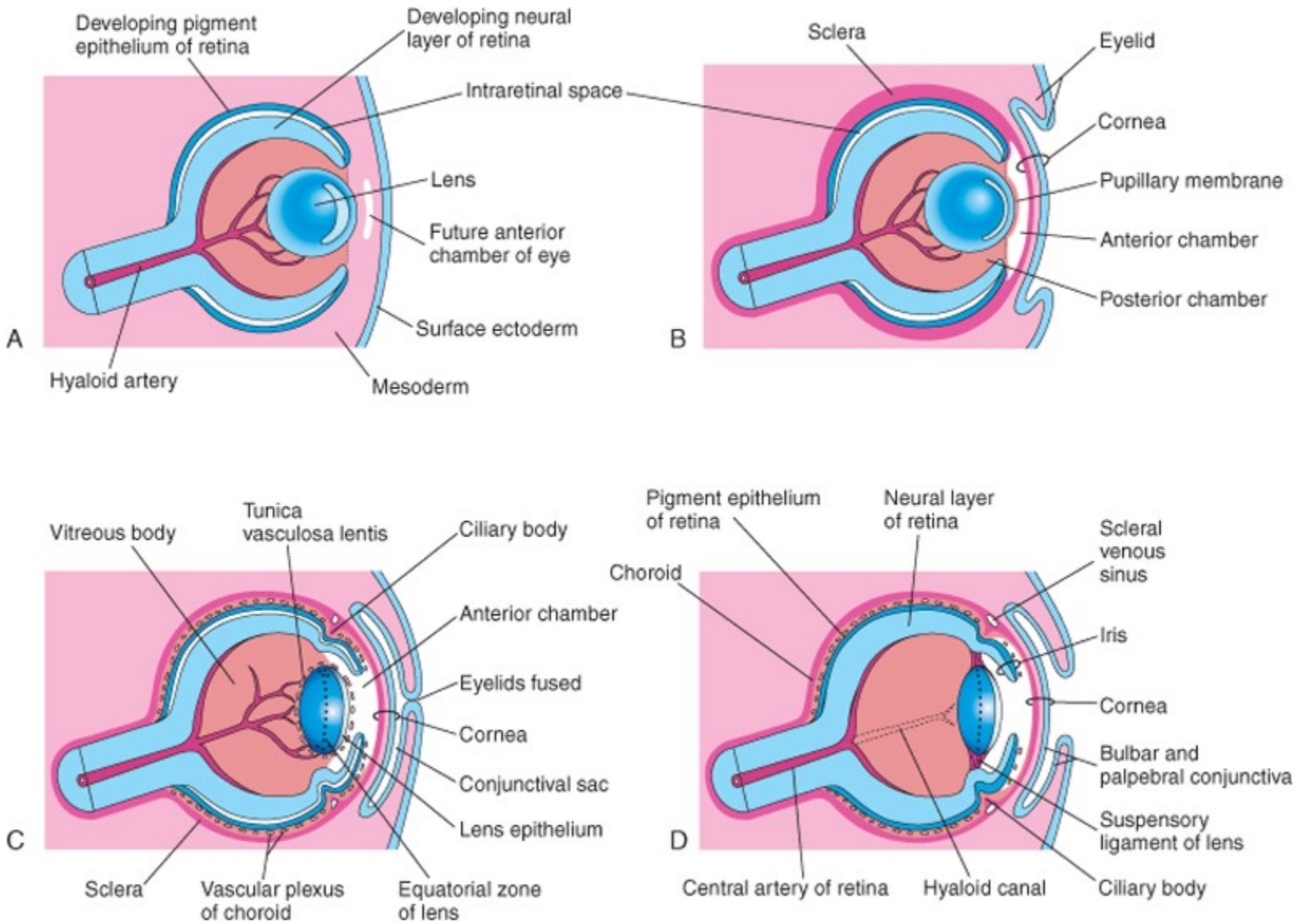

© Elsevier. Moore & Persaud: The Developing Human 8e - www.studentconsult.com

- The **vitreous body** forms within the cavity of the optic cup.
  - It is composed of **vitreous humor**, an avascular mass of transparent, gel-like, intercellular substance.
- The **primary vitreous humor** is derived from mesenchymal cells of **neural crest origin**.
- The primary vitreous humor does not increase but it is surrounded by a gelatinous **secondary vitreous humor**, generally believed to arise from the inner layer of the optic cup.
  - The secondary vitreous humor consists of primitive hyalocytes (vitreous cells), collagenous material, and traces of hyaluronic acid.

PERSISTENT PUPILLARY MEMBRANE

- Remnants of the pupillary membrane, which covers the anterior surface of the lens during the embryonic period, may persist as weblike strands of connective tissue or vascular arcades over the pupil in newborns, especially in premature infants.
- This tissue seldom interferes with vision and tends to atrophy.
- Very rarely the entire pupillary membrane persists, giving rise to congenital atresia of the pupil.

PERSISTENCE OF THE HYALOID ARTERY

- The distal part of the hyaloid artery normally degenerates as its proximal part becomes the central artery of the retina.
- If the distal part of the hyaloid artery persists, it may appear as a freely moving, nonfunctional vessel or as a wormlike structure projecting from the optic disc.
- Sometimes the hyaloid artery remnant may appear as a fine strand traversing the vitreous body.
- In other cases, a remnant of the artery may form a cyst.
- In unusual cases, the entire distal part of the artery persists and extends from the optic disc through the vitreous body to the lens.
- In most of these unusual cases, the eye is microphthalmic (very small).

CONGENITAL APHAKIA

- Absence of the lens is extremely rare and results from failure of the lens placode to form during the fourth week.
- Congenital aphakia could also result from failure of lens induction by the optic vesicle.

DEVELOPMENT OF THE AQUEOUS CHAMBERS

- The anterior chamber of the eye develops from a cleftlike space that forms in the mesenchyme located between the developing lens and cornea.
- The mesenchyme superficial to this space forms the substantia propria of the cornea and the mesothelium of the anterior chamber.
- After the lens is established, it induces the surface ectoderm to develop into the epithelium of the cornea and conjunctiva.

© Elsevier. Moore & Persaud: The Developing Human 8e - www.studentconsult.com

Photomicrograph of a sagittal section of the eye of an embryo (×100) at Carnegie stage 18, approximately 44 days. Observe that it is the posterior wall of the lens vesicle that forms the lens fibers. The anterior wall does not change appreciably as it becomes the anterior lens epithelium.

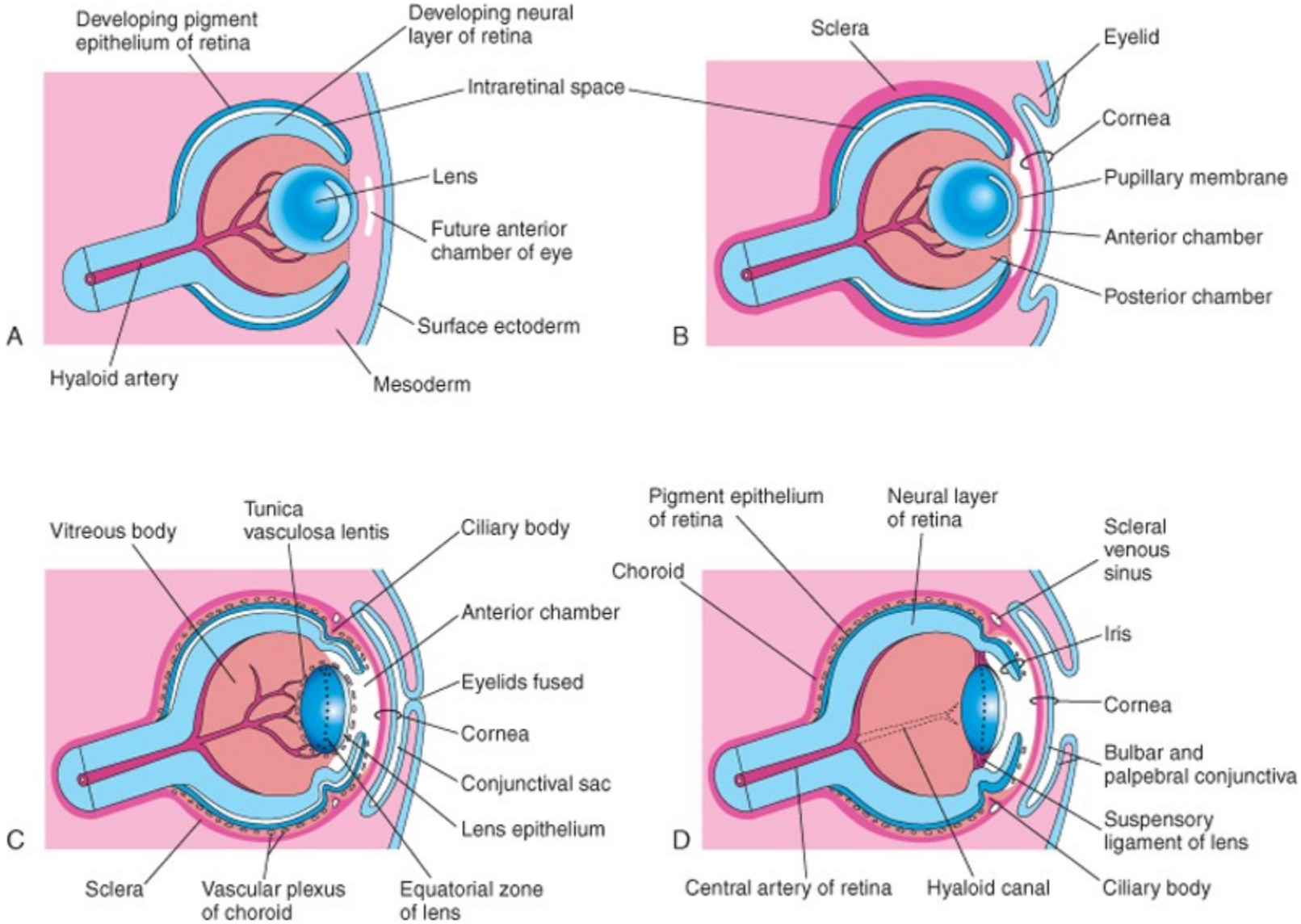

© Elsevier. Moore & Persaud: The Developing Human 8e - www.studentconsult.com

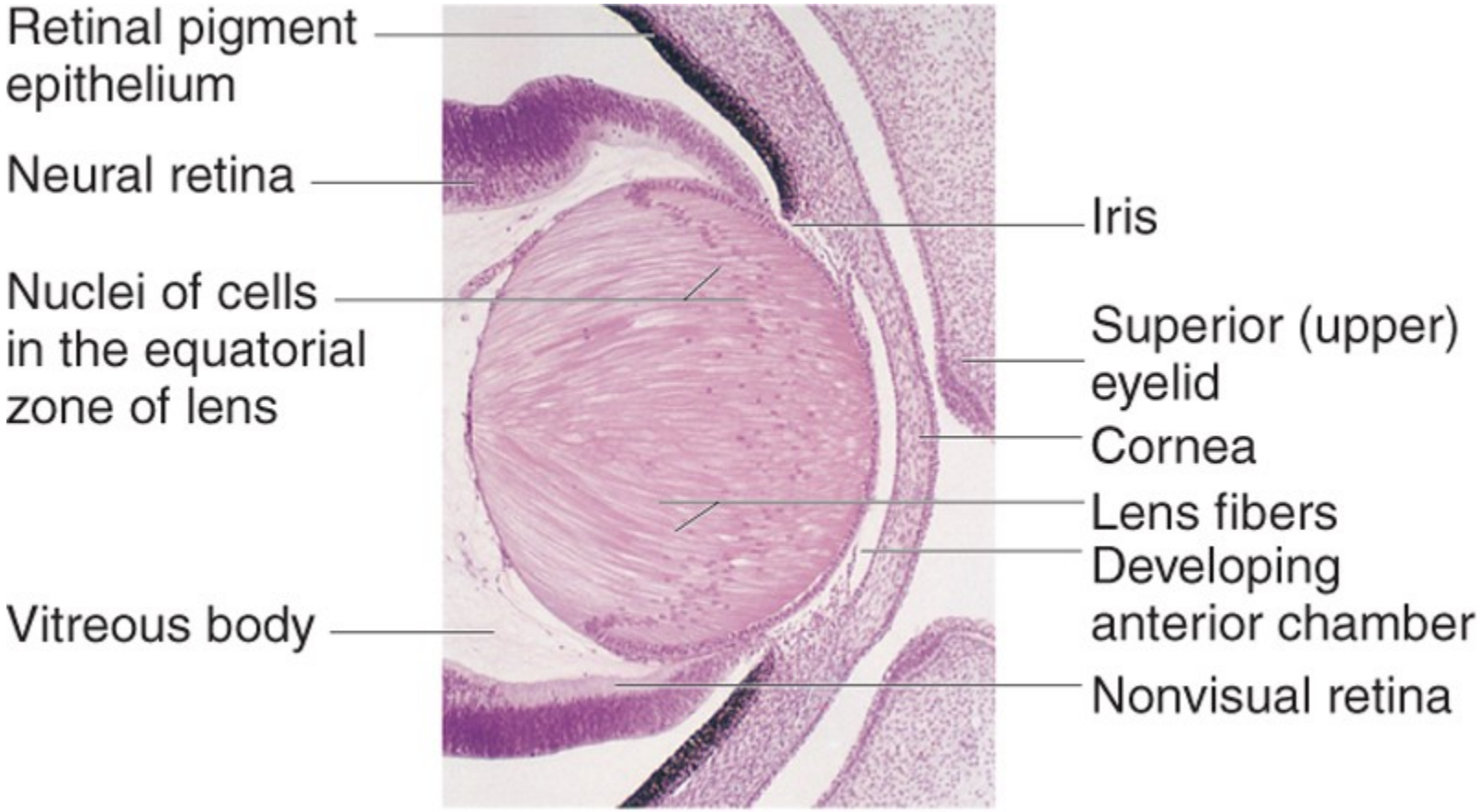

© Elsevier. Moore & Persaud: The Developing Human 8e - www.studentconsult.com

Photomicrograph of a portion of the developing eye. Observe that the lens fibers have elongated and obliterated the cavity of the lens vesicle. Note that the inner layer of the optic cup has thickened greatly to form the neural retina and that the outer layer is heavily pigmented (retinal pigment epithelium).

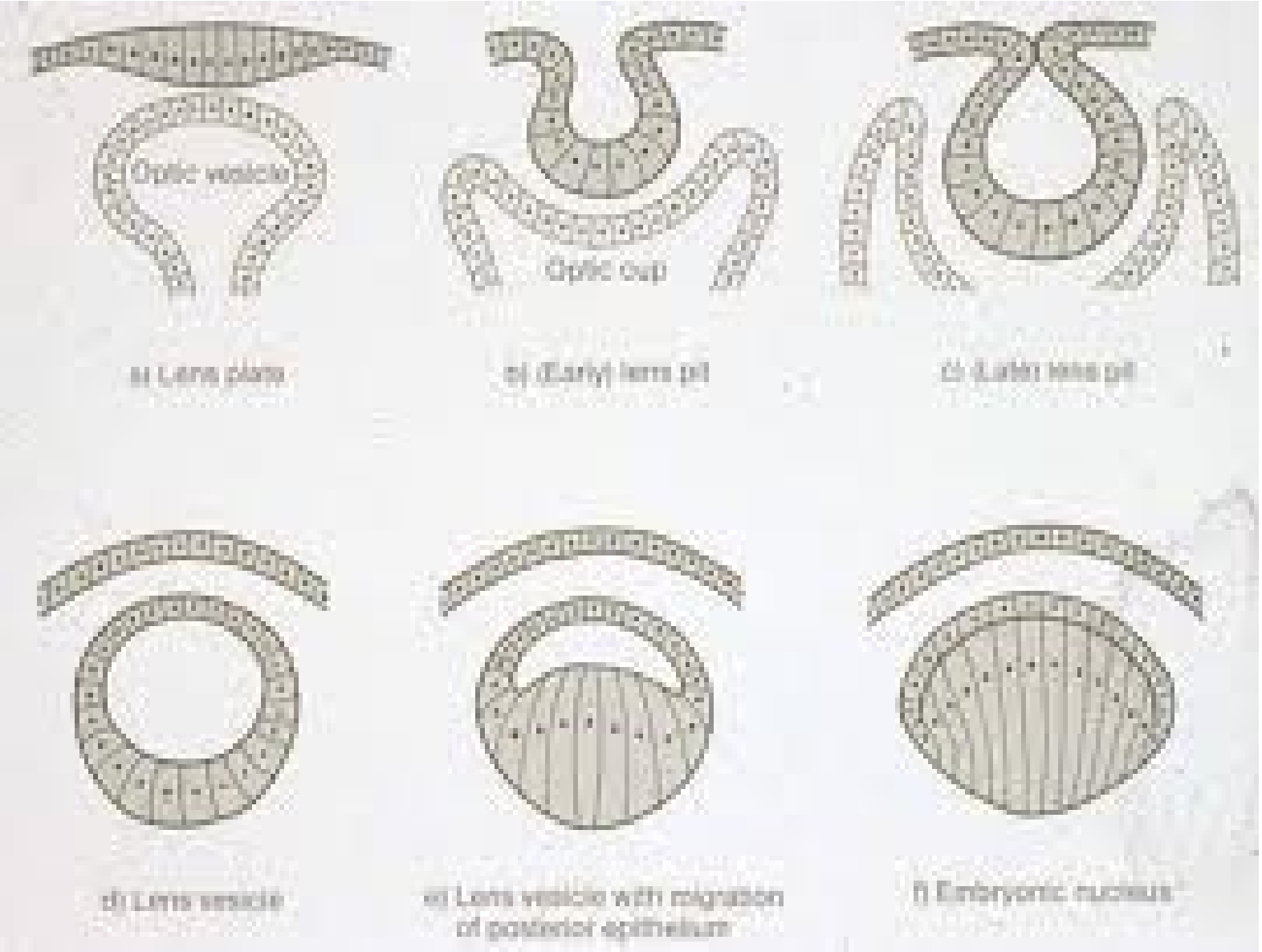
Optic vesicle
Optic cup
a) Lens plate
b) (Early) lens pit
c) (Late) lens pit
d) Lens vesicle
e) Lens vesicle with migration of posterior epithelium
f) Embryonic nucleus

- The **posterior chamber of the eye** develops from a space that forms in the mesenchyme posterior to the developing iris and anterior to the developing lens.
- When the pupillary membrane disappears and the pupil forms, the anterior and posterior chambers of the eye are able to communicate with each other through a circumferential **scleral venous sinus**.
- This vascular structure encircling the anterior chamber is the outflow site of aqueous humor from the anterior chamber of the eye to the venous system.

CONGENITAL GLAUCOMA

- Abnormal elevation of intraocular pressure in newborn infants usually results from abnormal development of the drainage mechanism of the aqueous humor during the fetal period.
- Intraocular tension rises because of an imbalance between the production of aqueous humor and its outflow.
- This imbalance may result from abnormal development of the scleral venous sinus.
- Congenital glaucoma is genetically heterogeneous, but the condition may result from a rubella infection during early pregnancy.

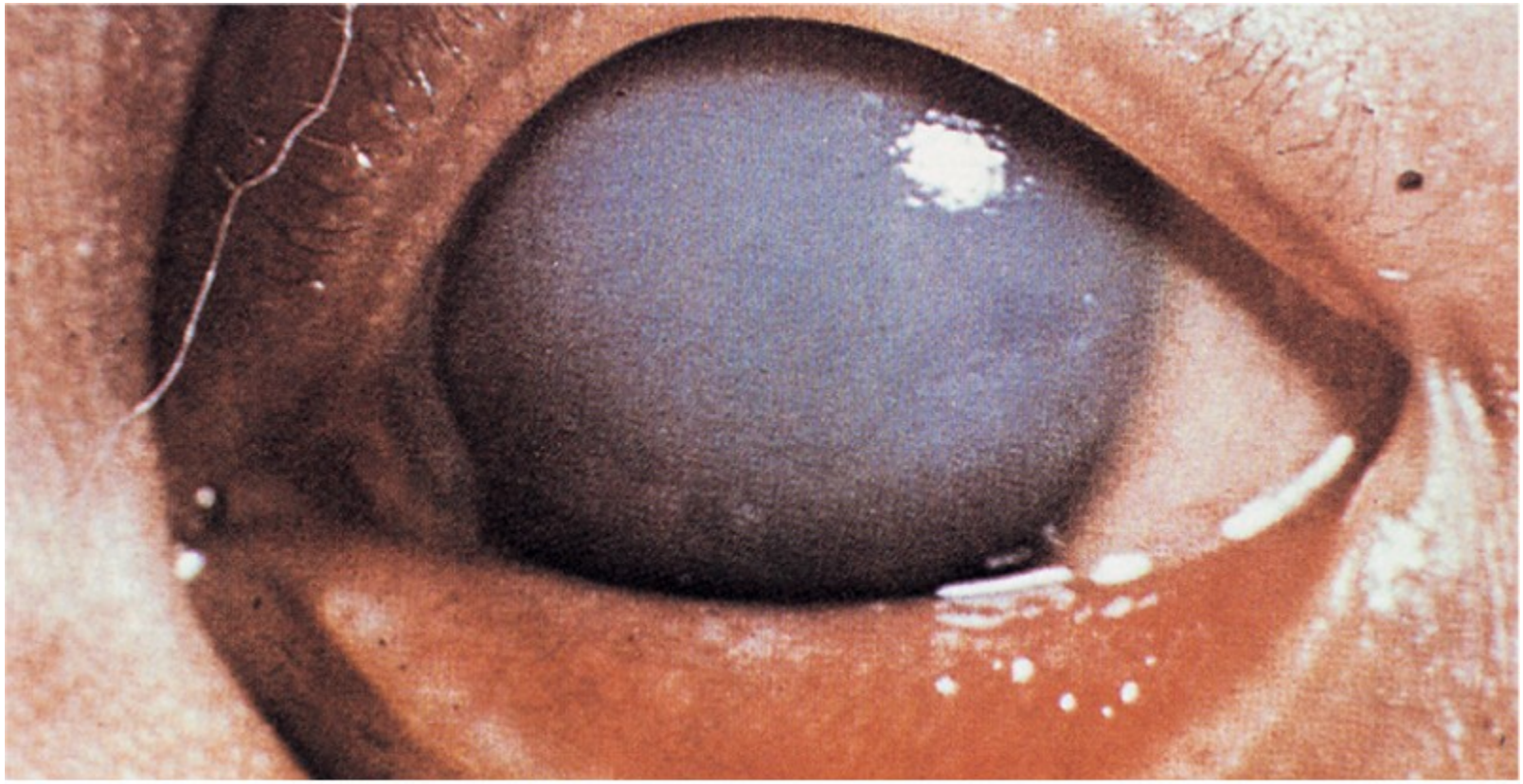

© Elsevier. Moore & Persaud: The Developing Human 8e - www.studentconsult.com

CONGENITAL CATARACTS

- In this condition, the lens is opaque and frequently appears grayish white.
- Without treatment, blindness results.
- Many lens opacities are inherited, dominant transmission being more common than recessive or sex-linked transmission.
- Some congenital cataracts are caused by teratogenic agents, particularly the rubella virus, that affect early development of the lenses.
- The lenses are vulnerable to rubella virus between the fourth and seventh weeks, when primary lens fibers are forming.

© Elsevier. Moore & Persaud: The Developing Human 8e - www.studentconsult.com

- Physical agents, such as **radiation**, can also damage the lens and produce cataracts.
- Another cause of cataract is an enzymatic deficiency-**congenital galactosemia**.
  - These cataracts are not present at birth, but may appear as early as the second week after birth.
- Because of the enzyme deficiency, large amounts of galactose from milk accumulate in the infant's blood and tissues, causing injury to the lens and resulting in cataract formation.

- Treatment of cataracts requires surgery, typically at a very early age (younger than 4 months), to remove the damaged lens.
- In most cases, corrective eyewear is required, although some studies have shown that artificial intraocular lenses may be safely implanted.
- More than 70% of patients with bilateral congenital cataracts can attain reasonable visual acuity.
- Extended treatment with refractive correction and additional surgery may be required.

DEVELOPMENT OF THE CORNEA

- The cornea is induced by the lens vesicle.
- The inductive influence results in transformation of the surface ectoderm into the transparent, multilayered avascular cornea, the part of the fibrous tunic of the eye that bulges out of the orbit.
- The cornea is formed from three sources:
  - The external corneal epithelium, derived from surface ectoderm
  - The mesenchyme, derived from mesoderm, which is continuous with the developing sclera
  - Neural crest cells that migrate from the lip of the optic cup and differentiate into the corneal endothelium

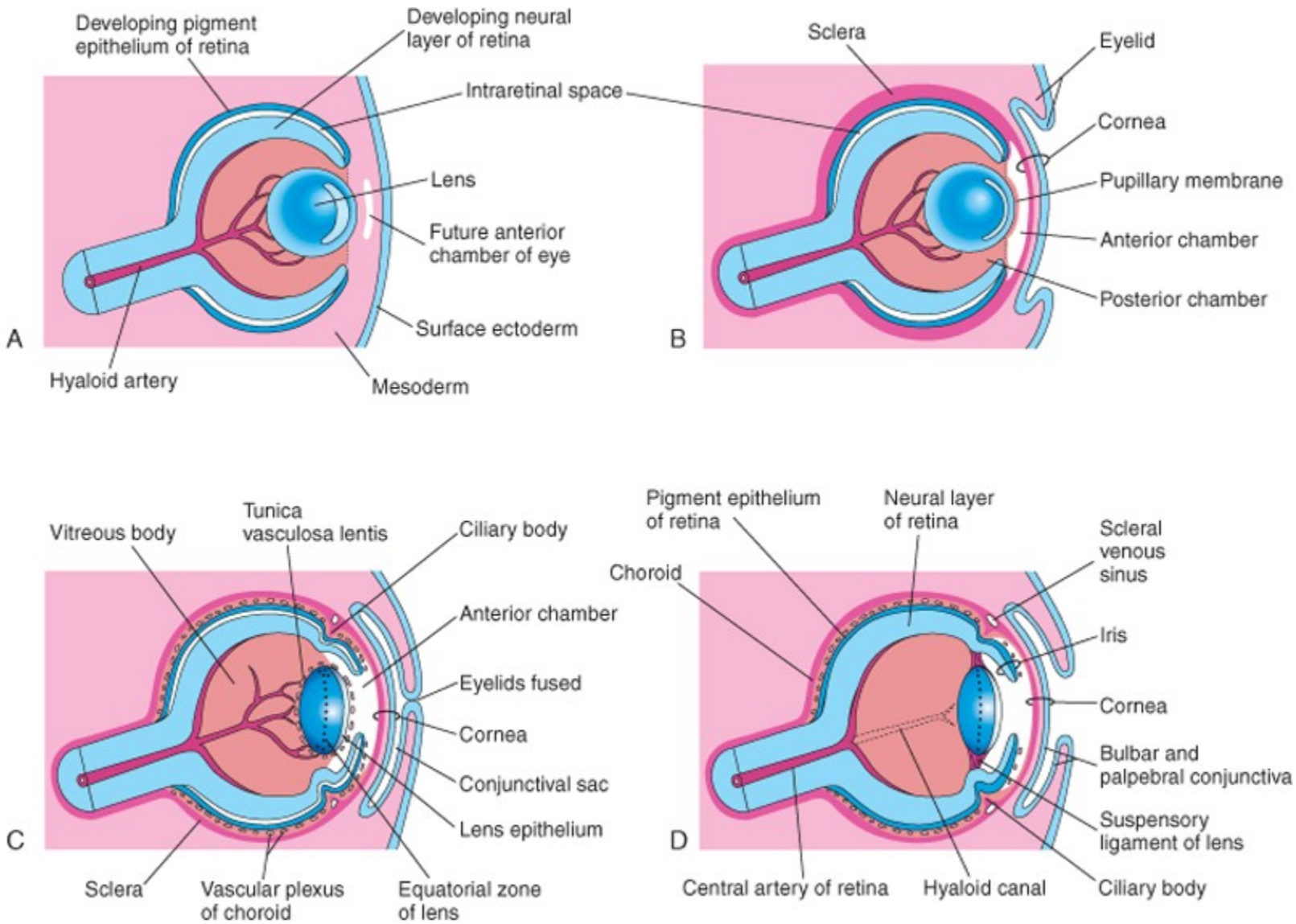

© Elsevier. Moore & Persaud: The Developing Human 8e - www.studentconsult.com

Stages (Hamburger-Hamilton) in the formation of the cornea in the chick embryo.

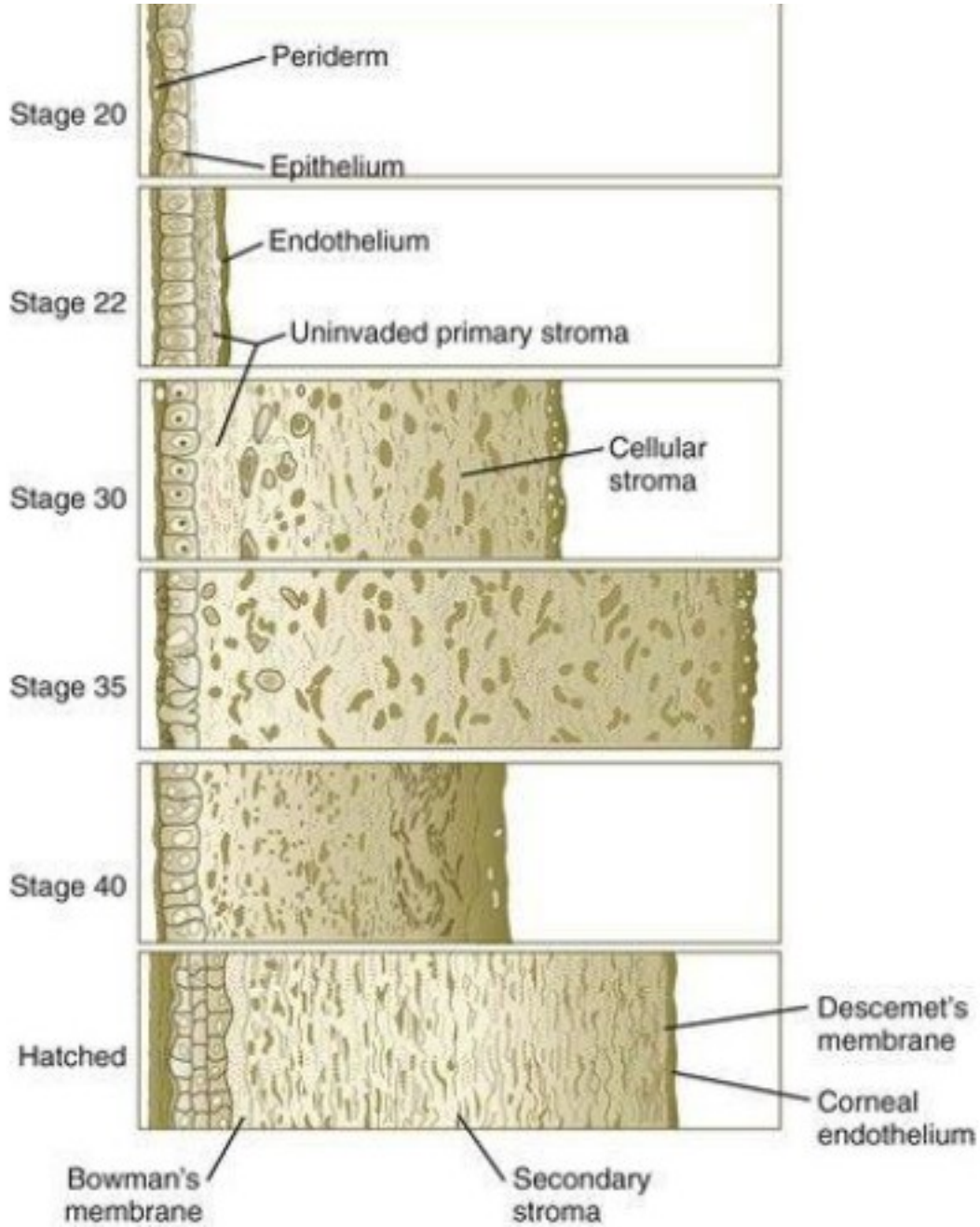

DEVELOPMENT OF THE CHOROID AND SCLERA

- The mesenchyme surrounding the optic cup (largely of neural crest origin) reacts to the inductive influence of the retinal pigment epithelium by differentiating into:
  - an inner vascular layer, the choroid,
  - an outer fibrous layer, the sclera.
- The sclera develops from a condensation of mesenchyme external to the choroid and is continuous with the stroma of the cornea.
- Toward the rim of the optic cup, the choroid becomes modified to form the cores of the ciliary processes, consisting chiefly of capillaries supported by delicate connective tissue.
- The first choroidal blood vessels appear during the 15th week; by the 23rd week, arteries and veins can be easily distinguished.

DEVELOPMENT OF THE EYELIDS

- The eyelids develop during the sixth week from:
  - neural crest cell mesenchyme
  - two cutaneous folds of ectoderm that grow over the cornea.
- The eyelids adhere to one another by the beginning of the 10th week and remain adherent until the 26th to the 28th week.
- While the eyelids are adherent, there is a closed conjunctival sac anterior to the cornea.
- As the eyelids open, the bulbar conjunctiva is reflected over the anterior part of the sclera and the surface epithelium of the cornea.
- The palpebral conjunctiva lines the inner surface of the eyelids.

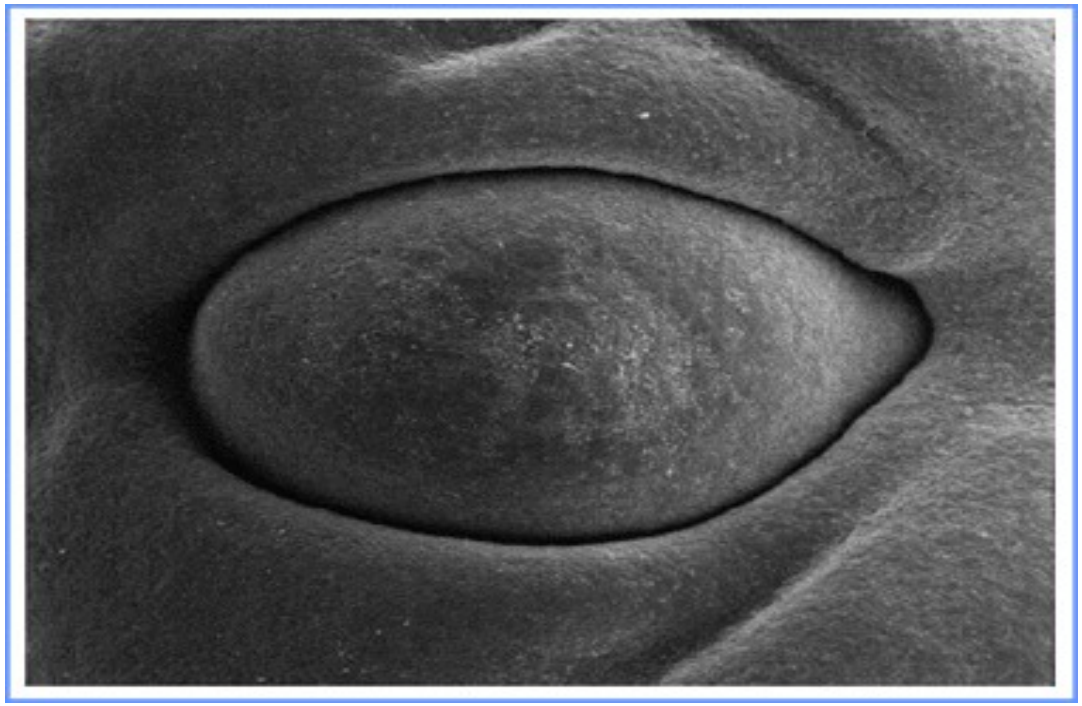

By the end of the embryonic period, eyelids begin to form.

- The **eyelashes** and **glands** in the eyelids are derived from the surface ectoderm in a manner similar to that described for other parts of the integument.
- The connective tissue and **tarsal plates** develop from mesenchyme in the developing eyelids.
- The orbicularis oculi muscle is derived from mesenchyme in the second pharyngeal arch and is supplied by its nerve (CN VII).

CONGENITAL PTOSIS OF THE EYELID

- Drooping of the superior (upper) eyelids at birth is relatively common.
- Ptosis (blepharoptosis) may result from failure of normal development of the levator palpebrae superioris muscle.
- Congenital ptosis may more rarely result from prenatal injury or dystrophy of the superior division of the oculomotor nerve (CN III), which supplies this muscle.
- If ptosis is associated with inability to move the eyeball superiorly, there is also failure of the superior rectus muscle of the eyeball to develop normally.
- Congenital ptosis may be transmitted as an autosomal dominant trait.
- Congenital ptosis is also associated with several syndromes.

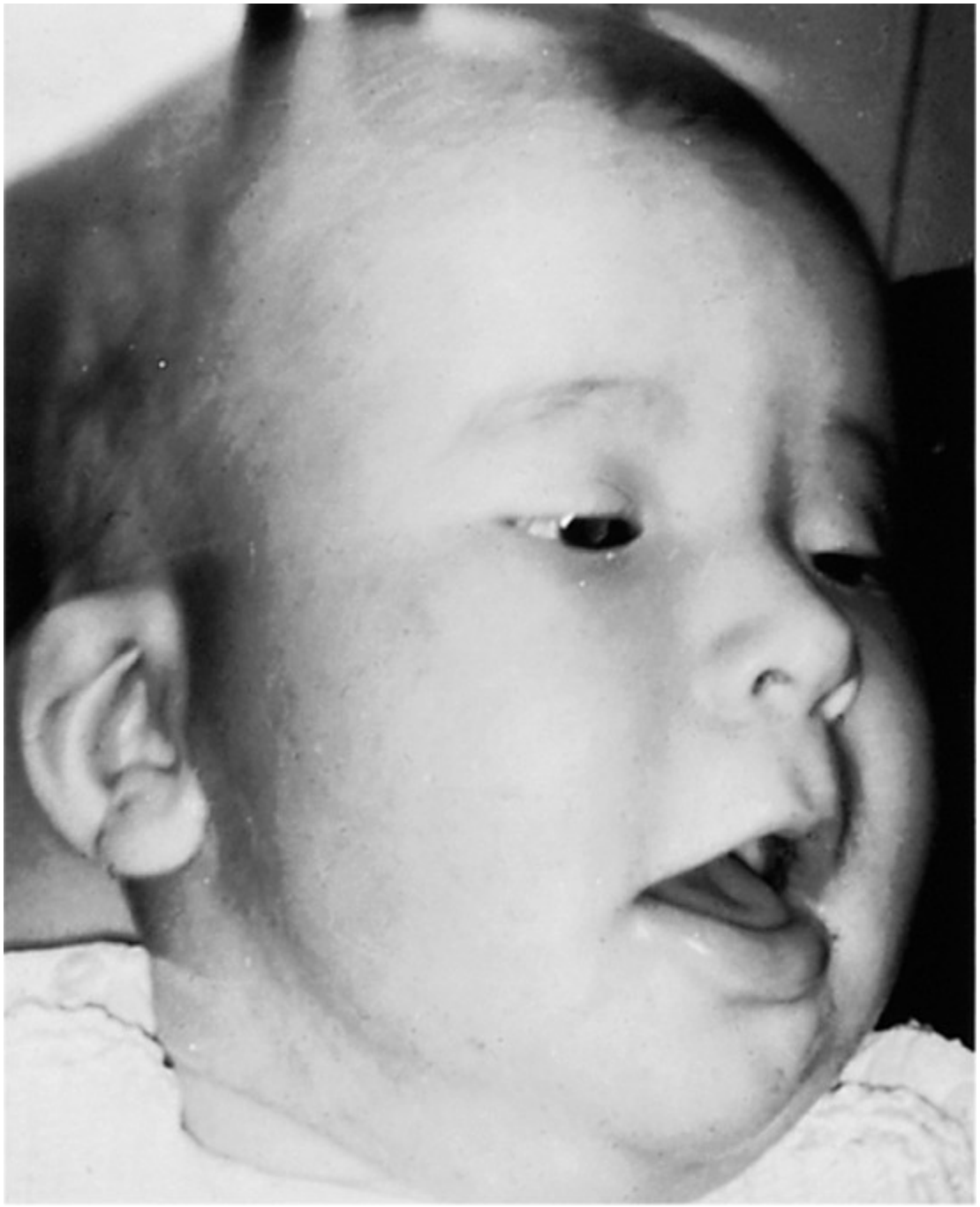

© Elsevier. Moore & Persaud: The Developing Human 8e - www.studentconsult.com

Coloboma of the Eyelid

- Large defects of the eyelid (palpebral colobomas) are uncommon.
- A coloboma is usually characterized by a small notch in the superior (upper) eyelid, but the defect may involve almost the entire lid.
- A coloboma of the inferior (lower) eyelid is rare.
- Palpebral colobomas appear to result from local developmental disturbances in the formation and growth of the eyelids.

Cryptophthalmos

- Cryptophthalmos results from congenital absence of the eyelids; as a result, skin covers the eye.
- The eyeball is small and defective, and the cornea and conjunctiva usually do not develop.
- Fundamentally, the defect means absence of the palpebral fissure (slit) between eyelids; usually there is varying absence of eyelashes and eyebrows and other eye defects.
- Cryptophthalmos is an autosomal recessive condition that is usually part of the cryptophthalmos syndrome.

DEVELOPMENT OF THE LACRIMAL GLANDS

- At the superolateral angles of the orbits, the lacrimal glands develop from a number of solid buds from the surface ectoderm.
- The buds branch and become canalized to form the nasolacrimal ducts.
- The lacrimal glands are small at birth and do not function fully until approximately 6 weeks; hence, the newborn infant does not produce tears when it cries.
- Tears are often not present with crying until 1 to 3 months.

CONGENITAL ANOMALIES OF THE EYE

- The type and severity of congenital eye anomalies depend on the embryonic stage during which development is disrupted.
- Several environmental teratogens cause congenital eye defects.
- Most common eye anomalies result from defects in closure of the retinal/choroid fissure.

CYCLOPIA

- In this very rare anomaly, the eyes are partially or completely fused, forming a single **median eye** enclosed in a single orbit.
- There is usually a tubular nose (**proboscis**) superior to the eye.
- **Cyclopia** (single eye) and **synophthalmia** (fusion of eyes) represent a spectrum of ocular defects in which the eyes are partially or completely fused.
- These severe eye anomalies are associated with other craniocerebral defects that are incompatible with life.
- Cyclopia appears to result from severe suppression of midline cerebral structures-**holoprosencephaly**-that develop from the cranial part of the neural plate.
- Cyclopia is transmitted by recessive inheritance.

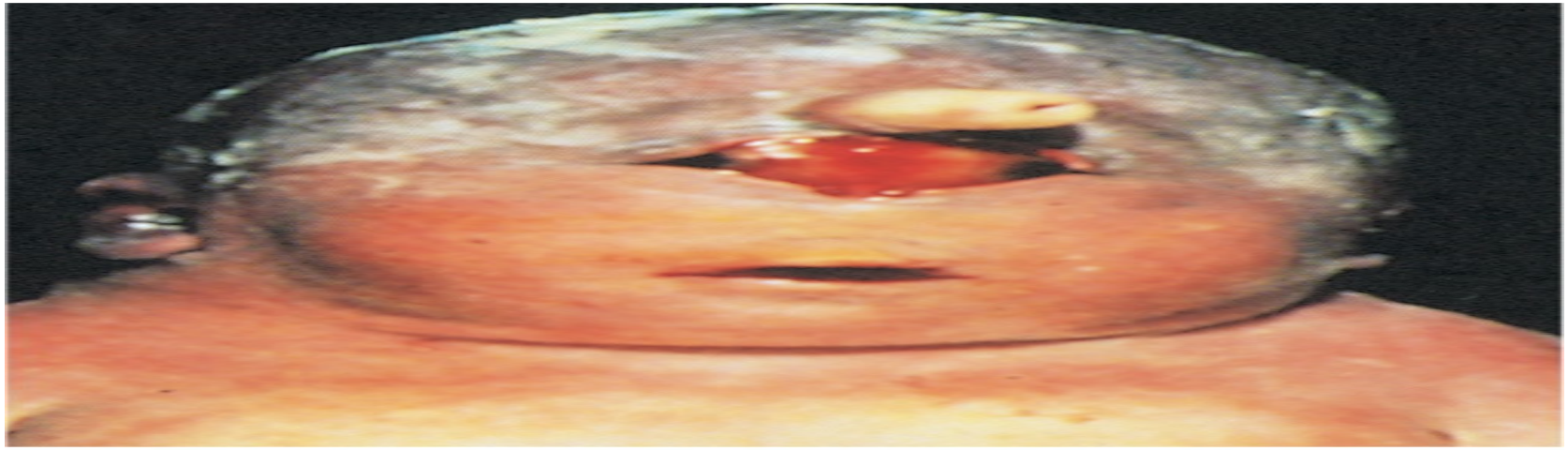

© Elsevier. Moore & Persaud: The Developing Human 8e - www.studentconsult.com

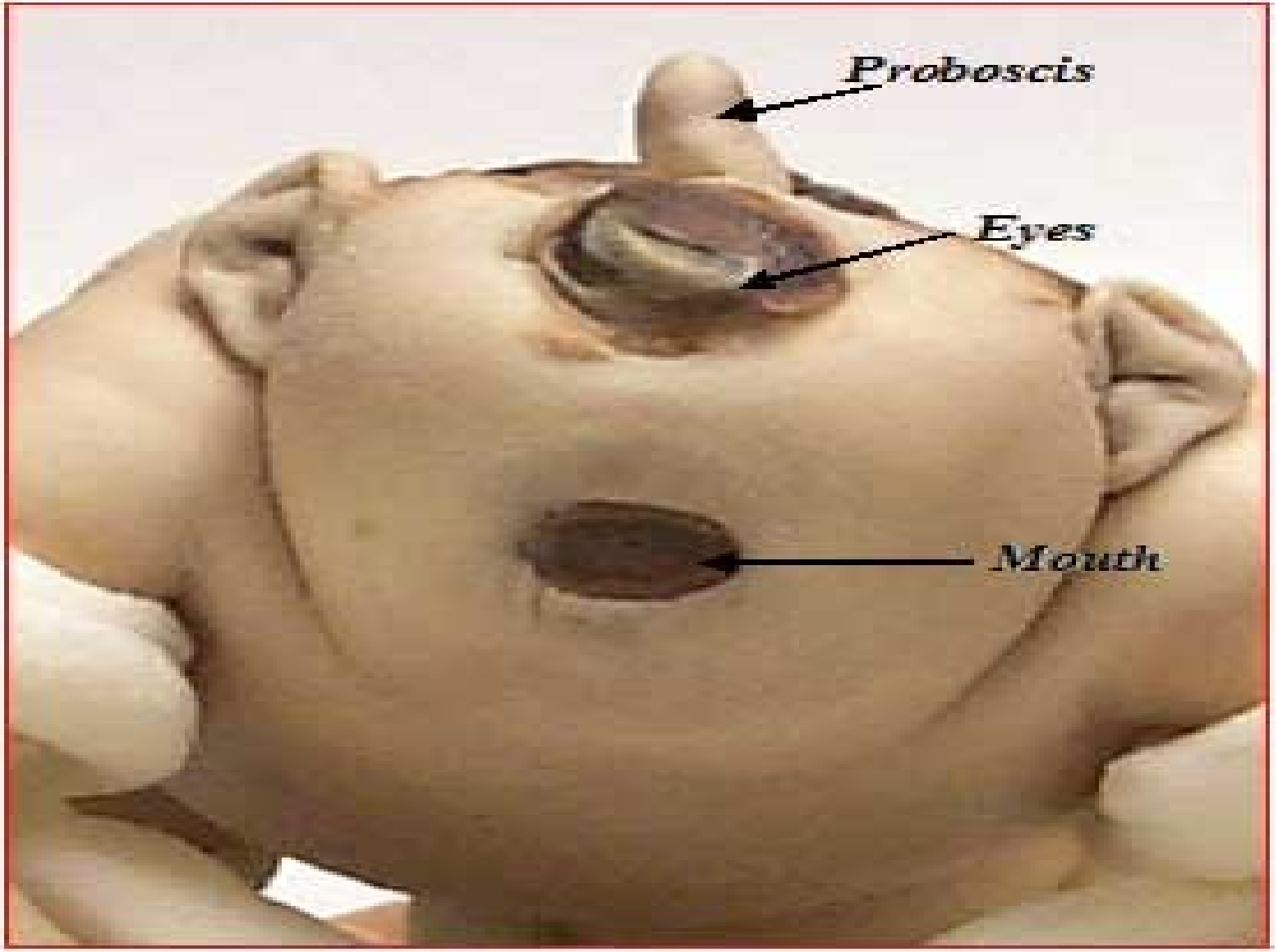
Proboscis
Eyes
Mouth

Microphthalmia

- Congenital microphthalmia is a heterogeneous group of eye anomalies.
- The eye may be very small with other ocular defects or it may be a normal-appearing rudimentary eye.
- The affected side of the face is underdeveloped and the orbit is small.
- Microphthalmia may be associated with other congenital anomalies (e.g., a facial cleft) and be part of a syndrome (e.g., trisomy 13).
- Severe microphthalmia results from arrested development of the eye before or shortly after the optic vesicle has formed in the fourth week.

- The eye is essentially underdeveloped and the lens does not form.
- Development arrested in the 6th week - the eye is larger, but the microphthalmos is associated with gross ocular defects.
- Development is arrested in the 8th week or during the early fetal period, simple microphthalmos results (small eye with minor ocular abnormalities).
- Some cases of microphthalmos are inherited: autosomal dominant, autosomal recessive, or X linked.
- Most cases of simple microphthalmia are caused by **infectious agents** (e.g., rubella virus, *Toxoplasma gondii*, and herpes simplex virus) that cross the placental membrane during the late embryonic and early fetal periods.

Anophthalmia

- Congenital absence of the eye - a rare condition.
- The eyelids form, but no eyeball develops.
- This severe defect is usually accompanied by other severe craniocerebral anomalies.
- In **primary anophthalmos**, eye development is arrested early in the fourth week and results from failure of the optic vesicle formation.
- In **secondary anophthalmos**, development of the forebrain is suppressed and absence of the eye or eyes is one of several associated anomalies.

© Elsevier. Moore & Persaud: The Developing Human 8e - www.studentconsult.com

DEVELOPMENT OF EAR

Prof P Gichangi

February 2017

OBJECTIVES

- Understand development of the ear
- Understand ear related congenital malformation

Anatomic parts

- *External ear*, consisting of the:
  - auricle (pinnae),
  - external acoustic meatus (passage),
  - the external layer of the tympanic membrane (eardrum)
- *Middle ear*, consisting of:
  - three small auditory ossicles (ear bones)
  - the internal layer of the tympanic membranes
- *Internal ear*, consisting of:
  - the vestibulocochlear organ

Development of Internal Ear

- First part of the ears to develop.
- Early in the 4th week, a thickening of surface ectoderm, the **otic placode**, appears on each side of the rhombencephalon-myelencephalon.
- Formation of otic placode is induced by signals from the paraxial mesoderm and notochord.
- Each otic placode soon invaginates forming **otic pit** and sinks deep to the surface ectoderm into the underlying mesenchyme.
- The edges of the pit soon come together and fuse to form an **otic vesicle**-the *primordium of the membranous labyrinth*.
- The otic vesicle loses its connection with the surface ectoderm.
- A diverticulum grows from the vesicle and elongates to form the **endolymphatic duct** and **sac**.
- The otic vesicles has two parts:
  - Dorsal **utricular parts**, from which the small endolymphatic ducts, utricles, and semicircular ducts arise
  - Ventral **saccular parts**, which give rise to the saccules and cochlear ducts

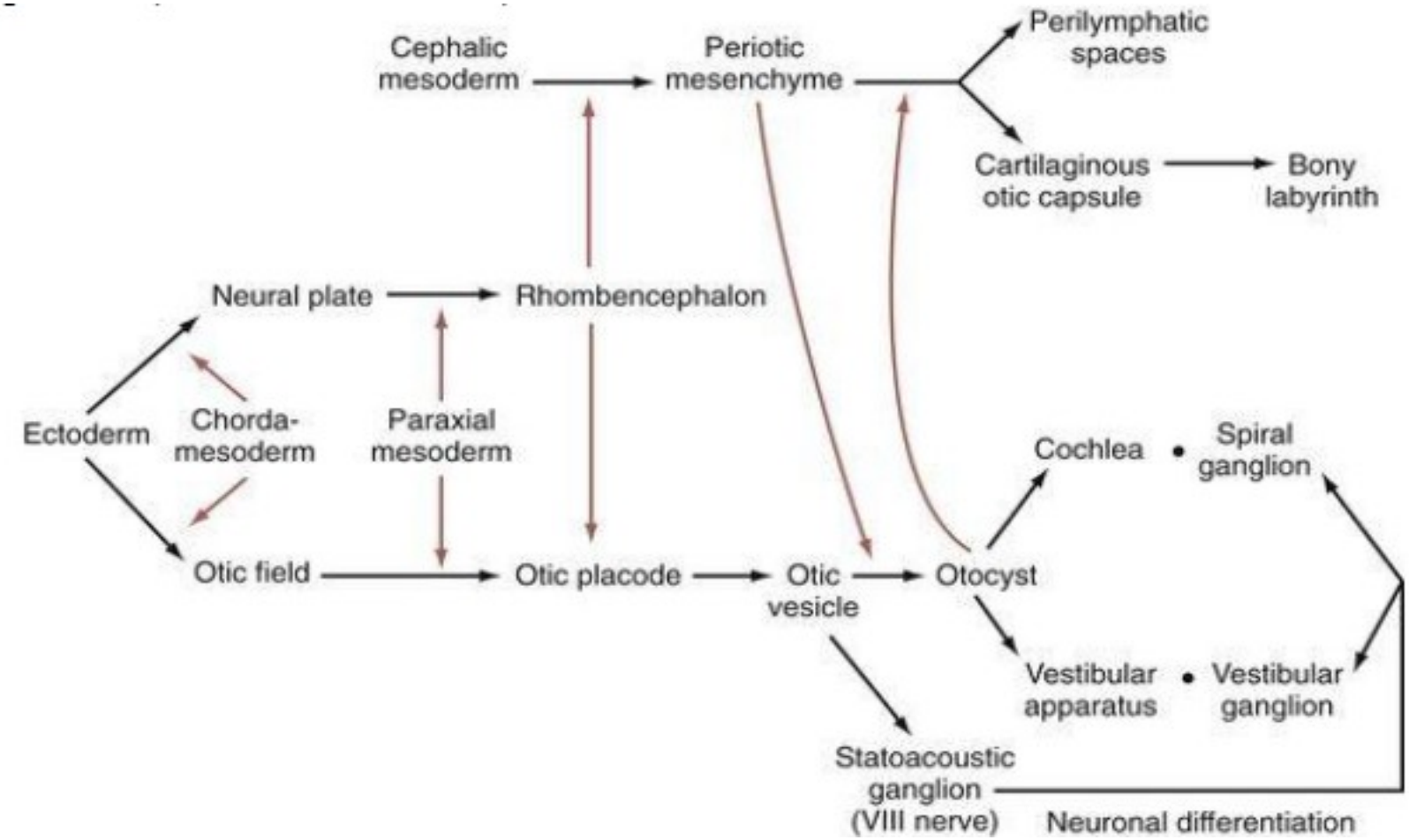

Flow chart of major inductive events and tissue transformations in the developing ear. *Colored arrows* refer to inductive events.

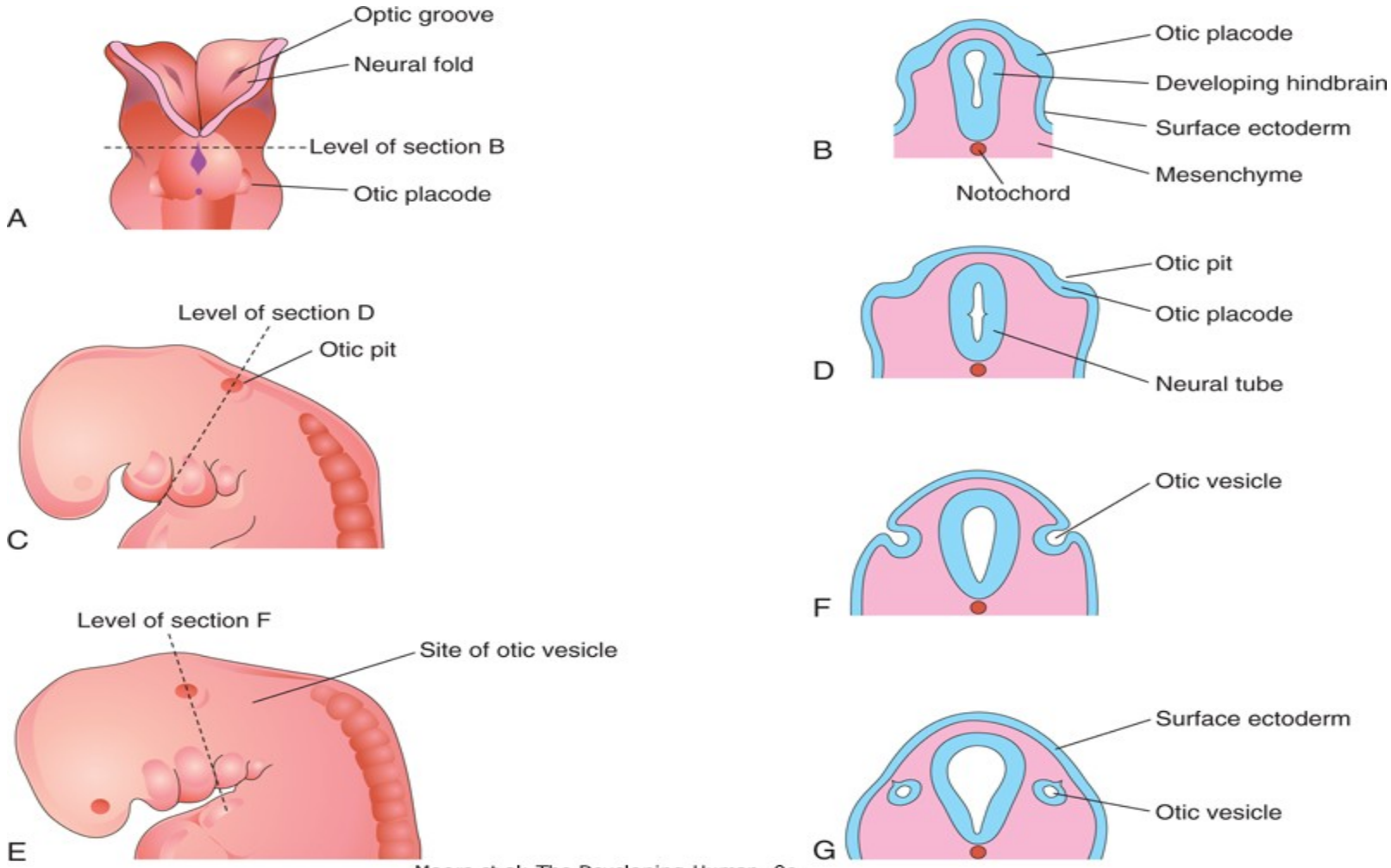

Moore et al: The Developing Human, 9e.
Copyright © 2013 by Saunders, an imprint of Elsevier Inc.

Drawings illustrating early development of the internal ear. **A,** Dorsal view of an embryo at approximately 22 days, showing the otic placodes. **B, D, F,** and **G,** Schematic coronal sections illustrating successive stages in the development of otic vesicles. **C** and **E,** Lateral views of the cranial region of embryos, at approximately 24 and 28 days, respectively.

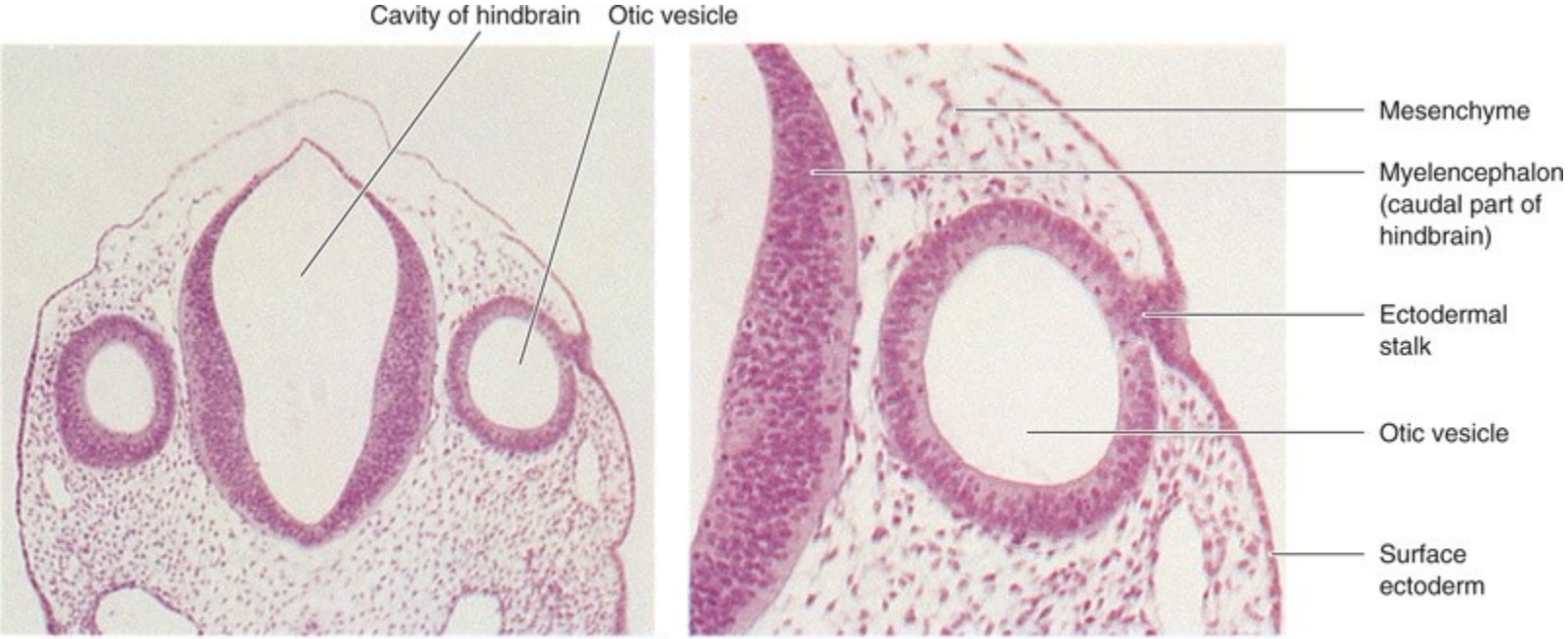

Moore et al: The Developing Human, 9e.
Copyright © 2013 by Saunders, an imprint of Elsevier Inc.

Left, Photomicrograph of a transverse section of an embryo (x55) at approximately 26 days. Observe the otic vesicles, the primordia of the membranous labyrinths, which give rise to the internal ears. *Right,* Higher magnification of the right otic vesicle (x120). Note the ectodermal stalk, which is still attached to the remnant of the otic placode. The otic vesicle will soon lose its connection with the surface ectoderm.

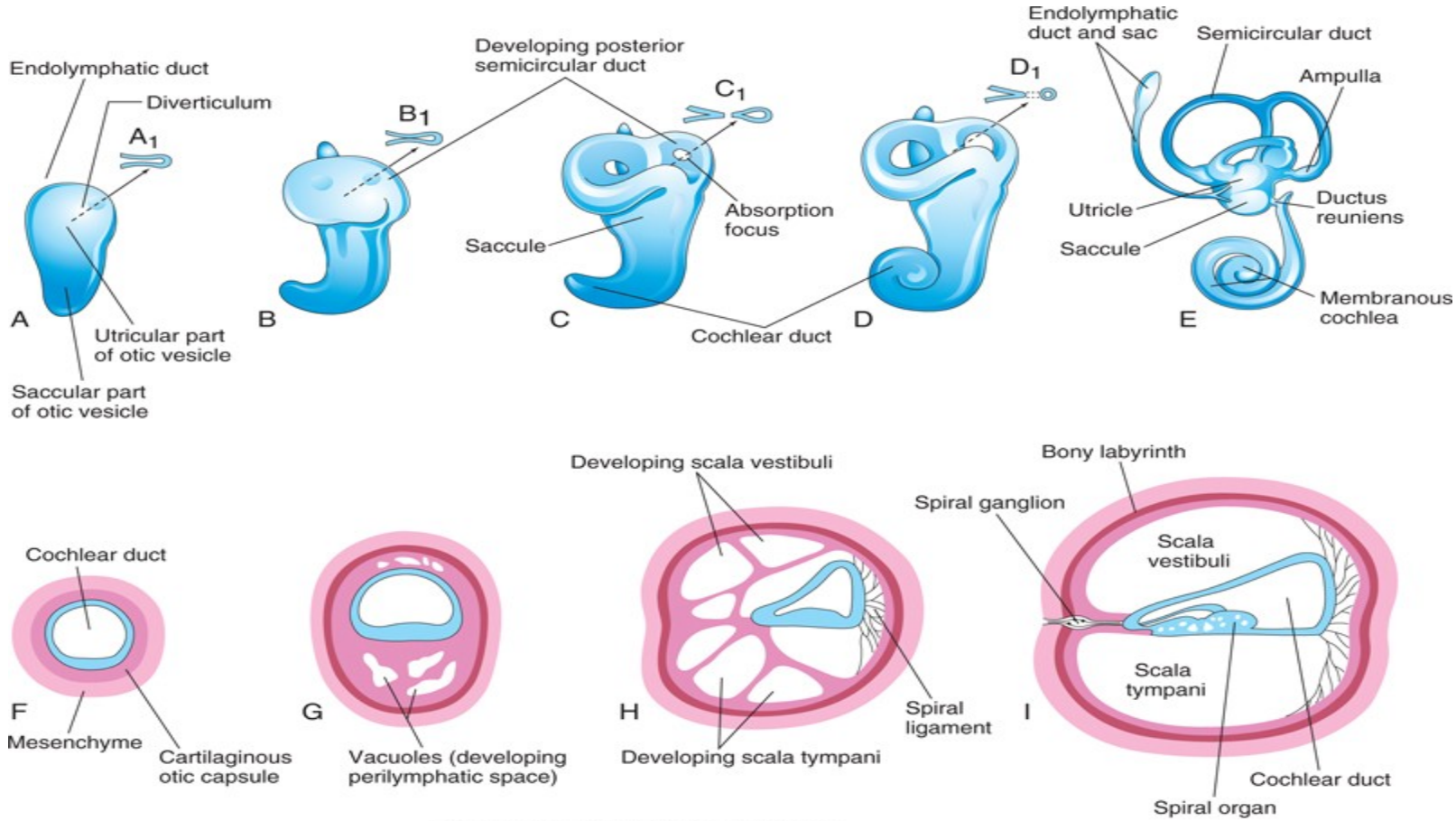

Moore et al: The Developing Human, 9e.
Copyright © 2013 by Saunders, an imprint of Elsevier Inc.

Drawings of the otic vesicles showing the development of the membranous and bony labyrinths of the internal ear. **A** to **E,** Lateral views showing successive stages in the development of the otic vesicle into the membranous labyrinth from the fifth to eighth weeks. **A** to **D,** Diagrammatic sketches illustrating the development of a semicircular duct. **F** to **I,** Sections through the cochlear duct showing successive stages in the development of the spiral organ and the perilymphatic space from the 8th to the 20th weeks.

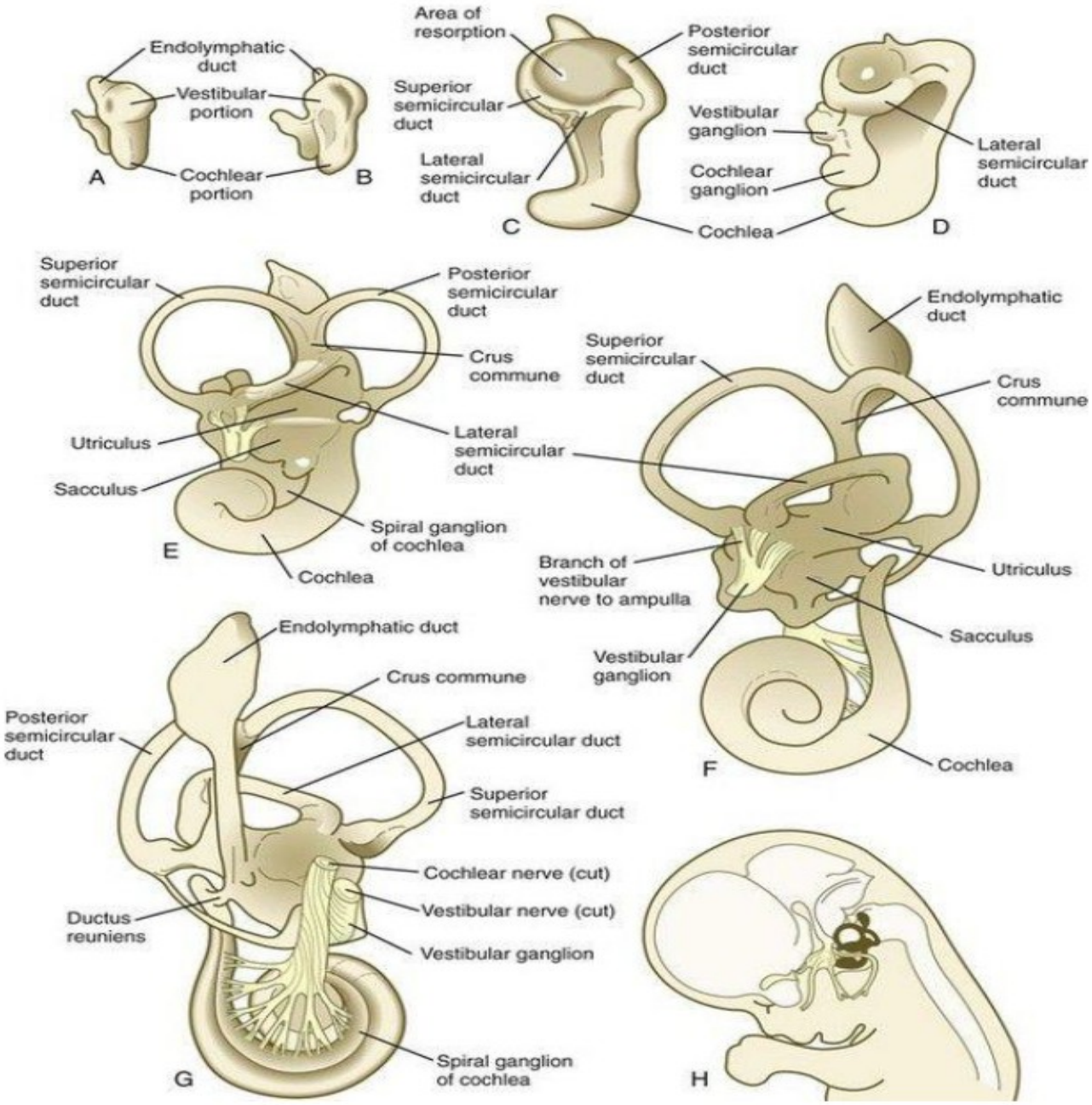
Endolymphatic duct
Vestibular portion
Cochlear portion
A
B
Area of resorption
Superior semicircular duct
Lateral semicircular duct
Posterior semicircular duct
Vestibular ganglion
Cochlear ganglion
Cochlea
C
D
Lateral semicircular duct
Superior semicircular duct
Posterior semicircular duct
Crus commune
Utriculus
Sacculus
Lateral semicircular duct
Spiral ganglion of cochlea
Cochlea
E
Endolymphatic duct
Superior semicircular duct
Crus commune
Branch of vestibular nerve to ampulla
Utriculus
Sacculus
Vestibular ganglion
Cochlea
F
Endolymphatic duct
Crus commune
Posterior semicircular duct
Lateral semicircular duct
Superior semicircular duct
Cochlear nerve (cut)
Vestibular nerve (cut)
Ductus reuniens
Vestibular ganglion
Spiral ganglion of cochlea
G
H

- Three disc-like diverticula grow out from the utricular parts of the **primordial membranous labyrinths**.
- Soon the central parts of these diverticula fuse and disappear.
- The peripheral unfused parts of the diverticula become the **semicircular ducts**, which are attached to the utricle and are later enclosed in the semicircular canals of the bony labyrinth.
- Localized dilatations, the **ampullae**, develop at one end of each semicircular duct.
- Specialized receptor areas-**cristae ampullares**-differentiate in the ampullae and the utricle and saccule (maculae utriculi and sacculi).
- From the **ventral saccular** part of the otic vesicle, a tubular diverticulum-the **cochlear duct**-grows and coils to form the **membranous cochlea**.

- A connection of the cochlea with the saccule, the **ductus reuniens**, soon forms.
- The **organ of Corti** differentiates from cells in the wall of the cochlear duct.
- Ganglion cells of the **vestibulocochlear nerve** (cranial nerve VIII) migrate along the coils of the membranous cochlea and form the **spiral ganglion** (of cochlea).
- Nerve processes extend from this ganglion to the spiral organ, where they terminate on the **hair cells**.
- The cells in the spiral ganglion retain their embryonic bipolar condition.
- Inductive influences from the otic vesicle stimulate the mesenchyme (mesoderm) around the otic vesicle to condense and differentiate into a **cartilaginous otic capsule**.

- With the enlargement of the **membranous labyrinth**, vacuoles appear in the cartilaginous otic capsule and soon coalesce to form the **perilymphatic space**.
- The membranous labyrinth is now suspended in **perilymph** (fluid in the perilymphatic space).
- The perilymphatic space, related to the cochlear duct, develops two divisions:
  - **scala tympani**
  - **scala vestibuli**.
- The cartilaginous otic capsule later ossifies (25 weeks) to form the **bony labyrinth** of the internal ear.
- The internal ear reaches its adult size and shape by the middle of the fetal period - 20-22 weeks.

Development of Middle Ear

- T**ubotympanic recess** develops from the first pharyngeal pouch.
- The proximal part of the tubotympanic recess forms the **pharyngotympanic tube** (auditory tube).
- The distal part of the recess expands and becomes the **tympanic cavity**, which gradually envelops the small bones of the middle ear-**auditory ossicles** (malleus, incus, and stapes), their tendons and ligaments, and the chorda tympani nerve.
- It has been suggested that, in addition to apoptosis in the middle ear, an epithelium-type organizer located at the tip of the tubotympanic recess probably plays a role in the early development of the middle ear and tympanic membrane.

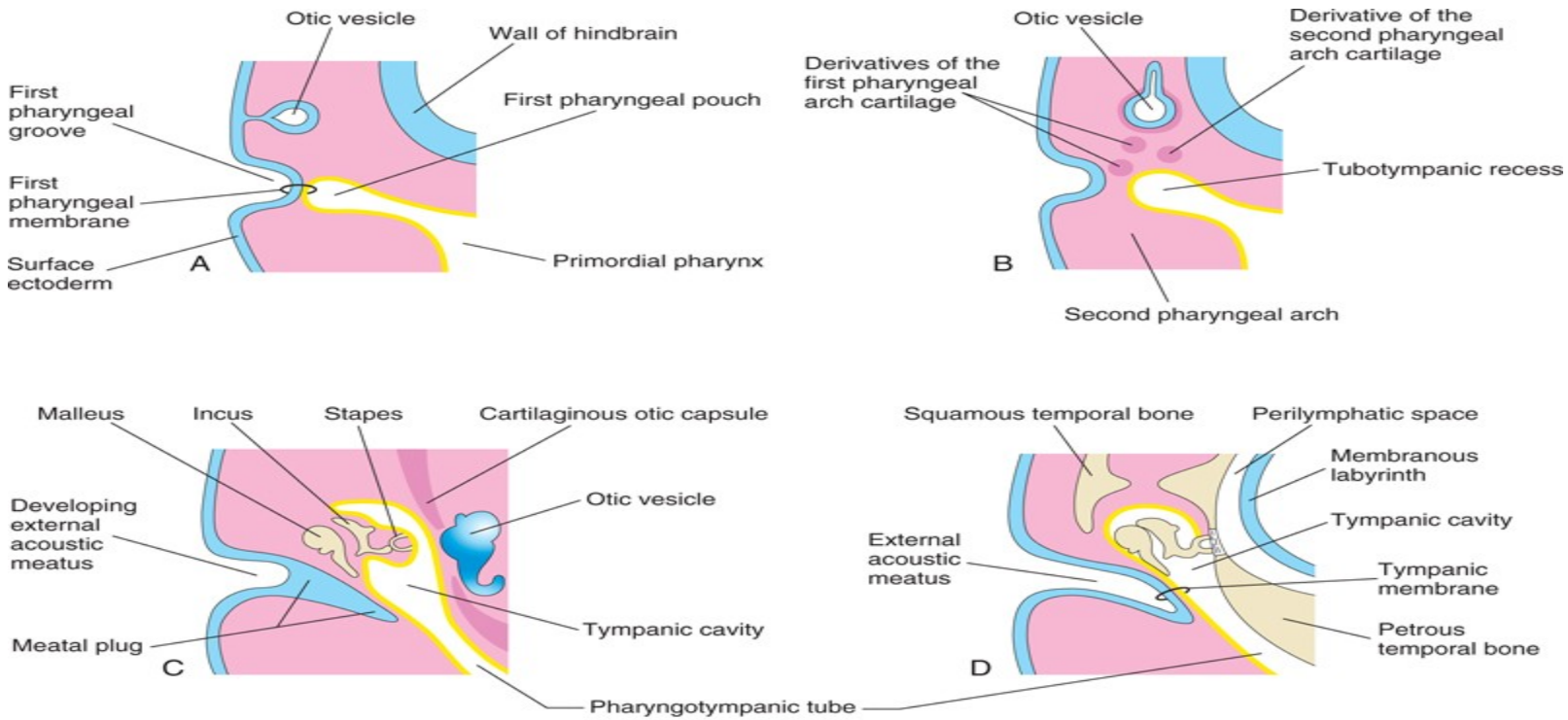

Moore et al: The Developing Human, 9e.
Copyright © 2013 by Saunders, an imprint of Elsevier Inc.

Schematic drawings illustrating development of the external and middle parts of the ear. Observe the relationship of these parts of the ear to the otic vesicle, the primordium of the internal ear. **A,** At 4 weeks, illustrating the relation of the otic vesicle to the pharyngeal apparatus. **B,** At 5 weeks, showing the tubotympanic recess and pharyngeal arch cartilages. **C,** Later stage, showing the tubotympanic recess (future tympanic cavity and mastoid antrum) beginning to envelop the ossicles. **D,** Final stage of ear development showing the relationship of the middle ear to the perilymphatic space and the external acoustic meatus. **Note that the tympanic membrane develops from three germ layers: surface ectoderm, mesenchyme, and endoderm of the tubotympanic recess.**

- Expansion of the **tympanic cavity** gives rise to the **mastoid antrum**, located in the petromastoid part of the temporal bone.
- The mastoid antrum is almost adult size at birth; however, no mastoid cells are present in neonates.
- By 2 years of age, the mastoid cells are well developed and produce conical projections of the temporal bones, the **mastoid processes**.
- The middle ear continues to grow through puberty.
- The **tensor tympani muscle**, attached to the malleus, is derived from mesenchyme in the first pharyngeal arch and is innervated by trigeminal nerve (CN V), the nerve of this arch.
- The **stapedius muscle** is derived from the second pharyngeal arch and is supplied by facial nerve (CN VII), the nerve of this arch.
  - *The signaling molecules FGF-8, endothelin-1, and Tbx1 are involved in middle ear development.*

Middle Ear bones

- 1st and 2nd pharyngeal arch cartilage (mesoderm) --> ossicles
- 1st (**Meckel's**): epitypanum ossicles
  - Head of malleus, body and short process of incus
- 2nd (**Reichert's**): mesotympanum ossicles
  - Long process malleus, long process incus, stapes superstructure
- Stapes **footplate**: otic capsule

Development of External Ear

- The **external acoustic meatus**, develops from the dorsal part of the first pharyngeal groove.
- The ectodermal cells at the bottom of this funnel-shaped tube proliferate to form a solid epithelial plate, the **meatal plug**.
- Degeneration of the central cells of this plug forms a cavity that becomes the internal part of the external acoustic meatus.
- The meatus, relatively short at birth, attains its adult length in approximately the 9th year.
- Tympanic membrane develops from three sources:
  - Ectoderm of the first pharyngeal groove
  - Endoderm of the tubotympanic recess, a derivative of the first pharyngeal pouch
  - Mesenchyme of the first and second pharyngeal arches which forms collagen in the membrane

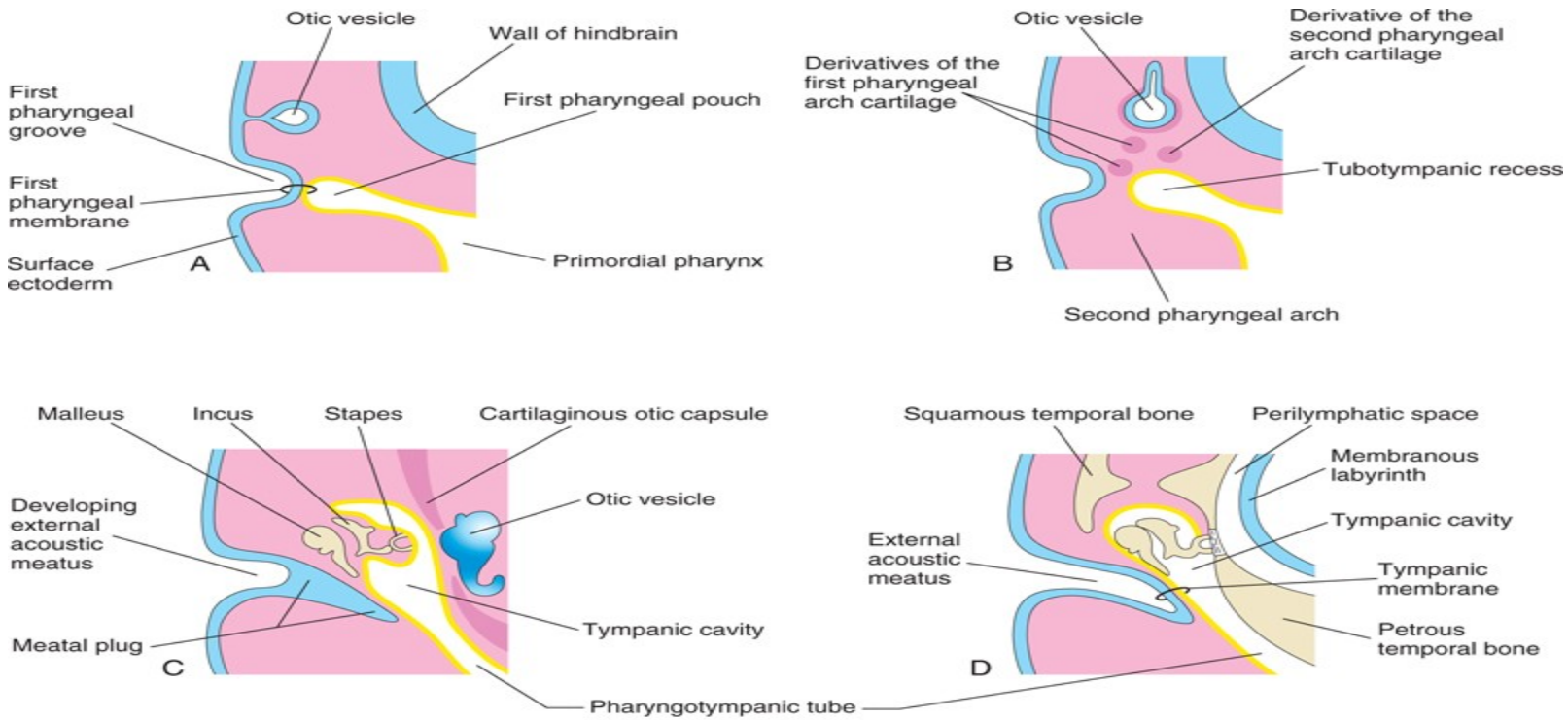

Moore et al: The Developing Human, 9e.
Copyright © 2013 by Saunders, an imprint of Elsevier Inc.

Schematic drawings illustrating development of the external and middle parts of the ear. Observe the relationship of these parts of the ear to the otic vesicle, the primordium of the internal ear. **A,** At 4 weeks, illustrating the relation of the otic vesicle to the pharyngeal apparatus. **B,** At 5 weeks, showing the tubotympanic recess and pharyngeal arch cartilages. **C,** Later stage, showing the tubotympanic recess (future tympanic cavity and mastoid antrum) beginning to envelop the ossicles. **D,** Final stage of ear development showing the relationship of the middle ear to the perilymphatic space and the external acoustic meatus. Note that the tympanic membrane develops from three germ layers: surface ectoderm, mesenchyme, and endoderm of the tubotympanic recess.

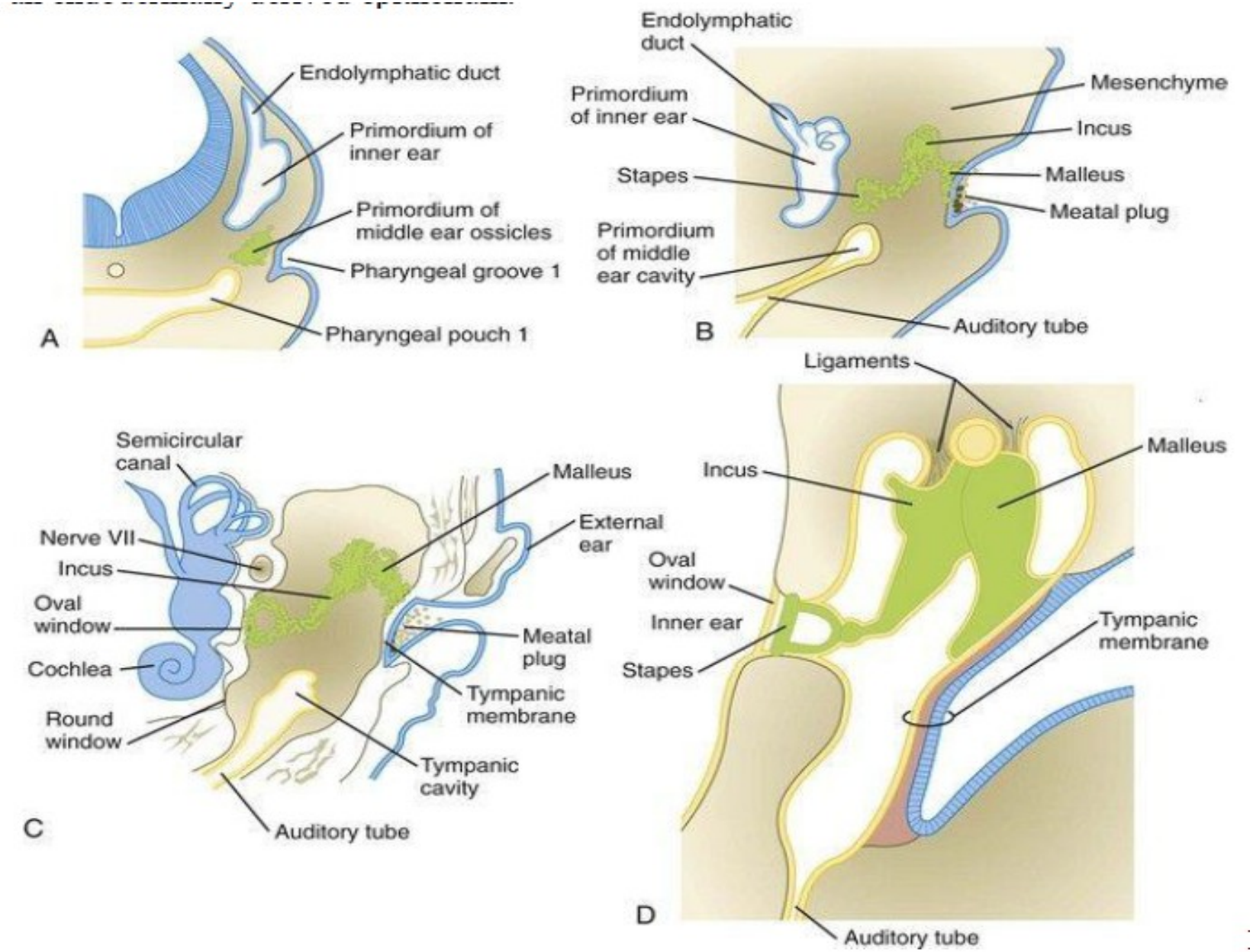
Endolymphatic duct
Primordium of inner ear
Primordium of middle ear ossicles
Pharyngeal groove 1
Pharyngeal pouch 1
A
Endolymphatic duct
Primordium of inner ear
Stapes
Primordium of middle ear cavity
Mesenchyme
Incus
Malleus
Meatal plug
Auditory tube
B
Semicircular canal
Nerve VII
Incus
Oval window
Cochlea
Round window
Malleus
External ear
Meatal plug
Tympanic membrane
Tympanic cavity
Auditory tube
C
Ligaments
Incus
Malleus
Oval window
Inner ear
Stapes
Tympanic membrane
D
Auditory tube

- The **auricle** (pinna), develops from mesenchymal proliferations in the first and second pharyngeal arches - **auricular hillocks** - surrounding the first pharyngeal groove .
- The **earlobule** (earlobe) of the auricle is the last part of the auricle to develop.
- The auricles begin to develop at the base of the neck.
- As the mandible develops, the auricles assume their normal position at the side of the head.
- The parts of the auricle derived from:
  - the first pharyngeal arch are supplied by its nerve, the mandibular branch of the **trigeminal nerve**;
  - the parts derived from the second arch are supplied by cutaneous branches of the cervical plexus, especially the **lesser occipital** and **greater auricular nerves**.
- The nerve of the second pharyngeal arch, the **facial nerve**, has few cutaneous branches; some of its fibers contribute to the sensory innervation of the skin in the mastoid region and probably in small areas on both aspects of the auricle.

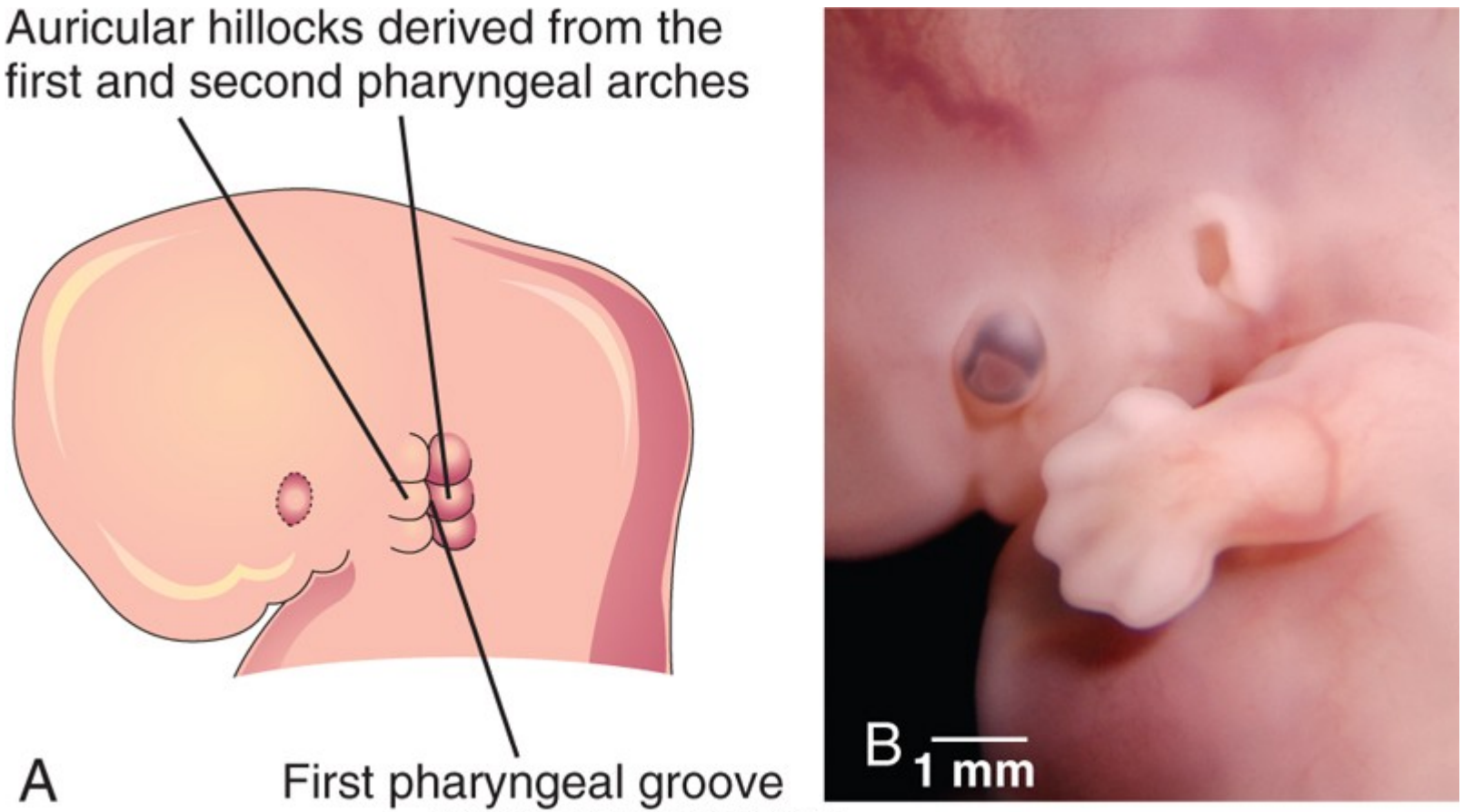

Moore et al: The Developing Human, 9e.
Copyright © 2013 by Saunders, an imprint of Elsevier Inc.

Illustration of the development of the auricle, the part of the external ear that is not within the head. **A,** At 6 weeks. Note that three auricular hillocks are located on the first pharyngeal arch and three on the second arch. **B,** Photograph of a 7-week embryo. Note the developing external ear.

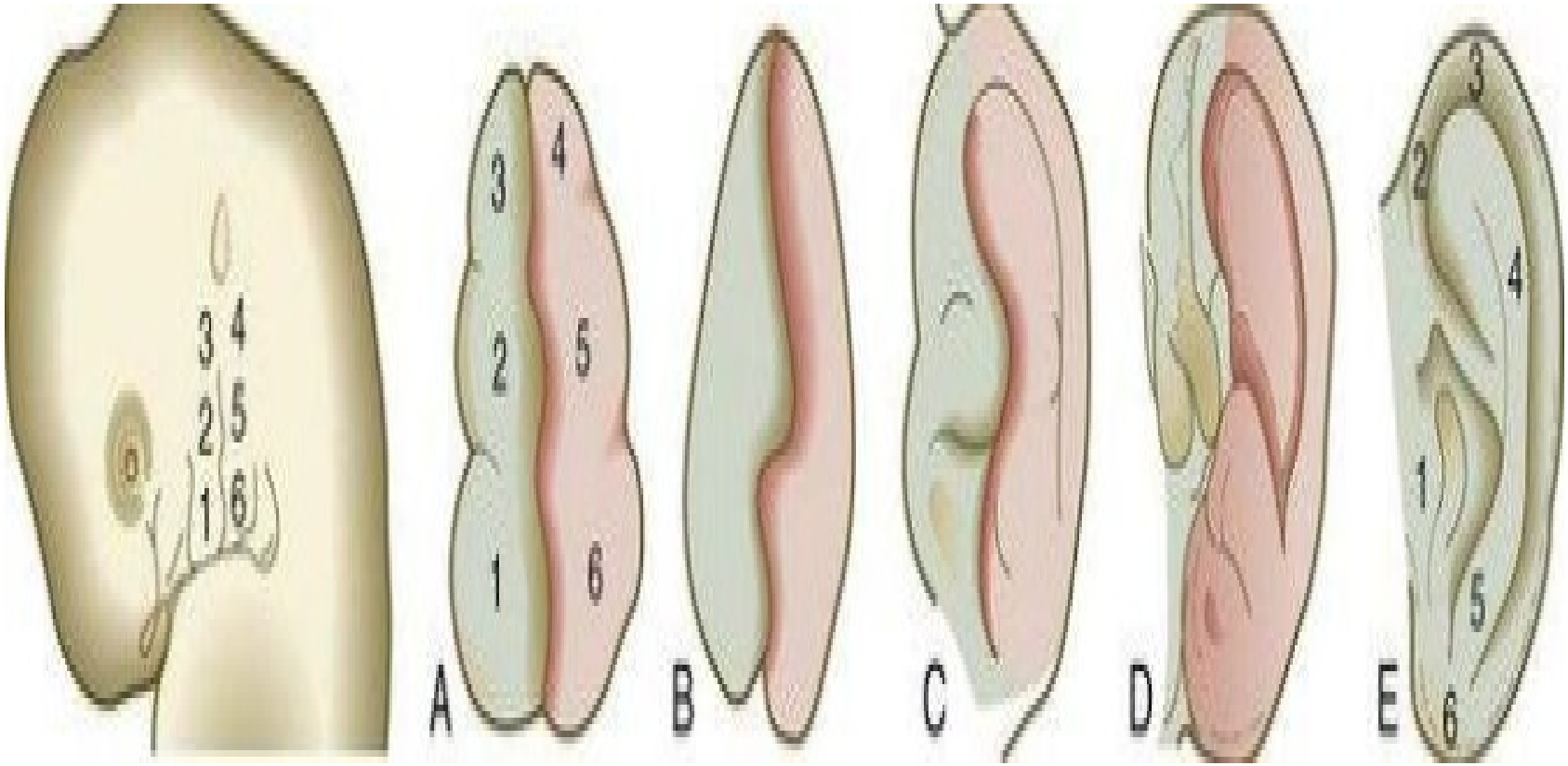

A to **E,** Stages in development of the external ear. Components derived from the mandibular arch (I) are *unshaded;* components derived from the hyoid arch (II) are *shaded*

Moore et al: The Developing Human, 9e.
Copyright © 2013 by Saunders, an imprint of Elsevier Inc.

A child with an auricular fistula relating to the first pharyngeal arch. Note the external orifice of the fistula below the auricle and the upward direction of the catheter (in sinus tract) toward the external acoustic meatus.

Auricle

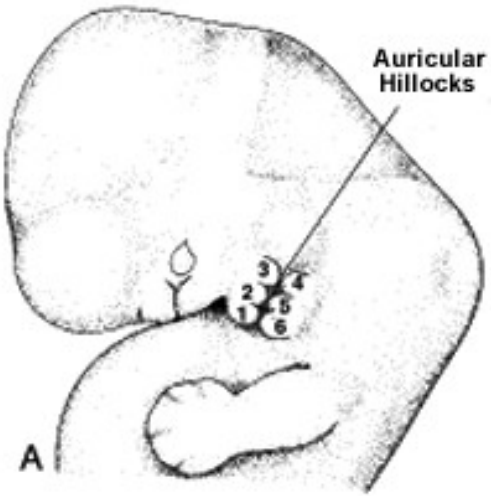

- 6 Hillocks of His (mesoderm)
- 1st pharyngeal arch
  - 1: Tragus
  - 2: Helical crus
  - 3: Helix
- 2nd pharyngeal arch
  - 4: antihelix
  - 5: antihelix
  - 6: antitragus

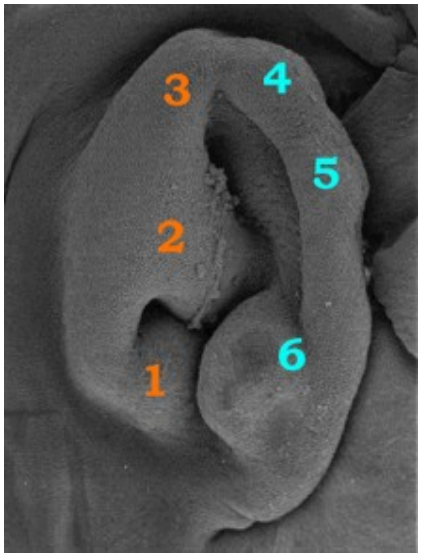

Auricle

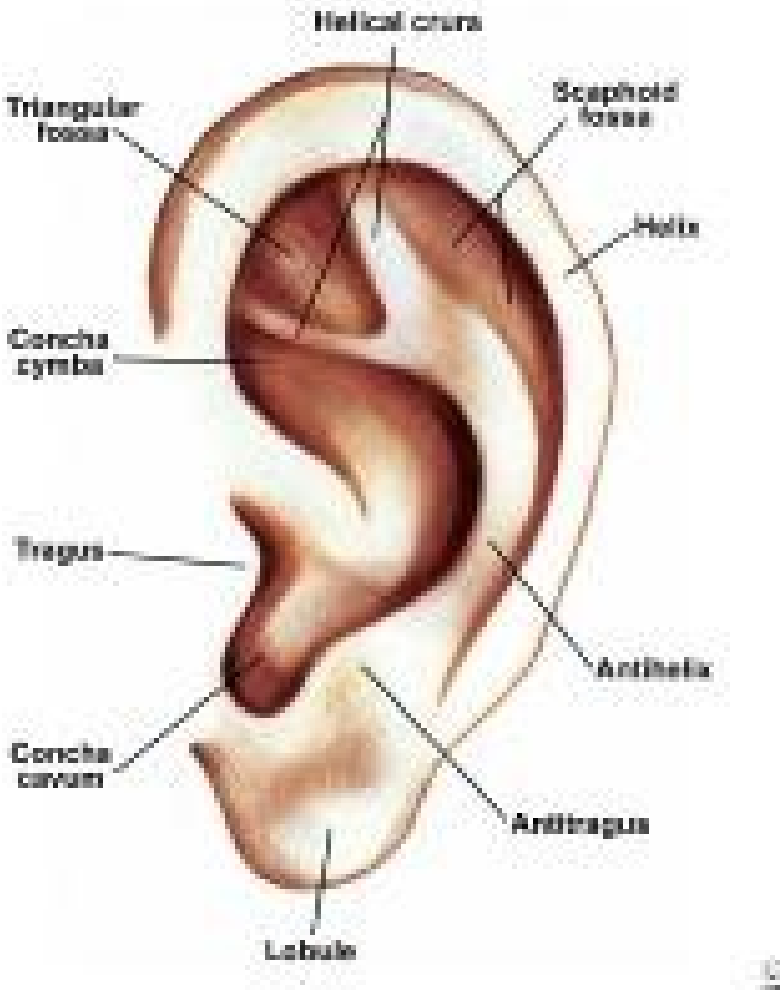
Helical crura
Triangular fossa
Scaphoid fossa
Helix
Concha cymba
Tragus
Antihelix
Concha cavum
Antitragus
Lobule

CONGENITAL DEAFNESS

- Approximately 3 in every 1000 newborns have significant hearing loss, of which there are many subtypes.
- Most types of congenital deafness are caused by genetic factors.
- Mutations in the *GJB2* gene are responsible for approximately 50% of nonsyndromic recessive hearing loss.
- Congenital deafness may be associated with several other head and neck defects as a part of the first arch syndrome.
- Abnormalities of the malleus and incus are often associated with this syndrome.
- A **rubella infection** during the 7th and 8th weeks, can cause defects of the spiral organ and deafness.
- **Congenital fixation of the stapes** results in conductive deafness in an otherwise normal ear.
  - Failure of differentiation of the annular ligament, which attaches the base of the stapes to the oval window (*fenestra vestibuli*), results in fixation of the stapes to the bony labyrinth.

AURICULAR ABNORMALITIES

- Severe defects of the external ear are rare, but minor deformities are common.
- There is a wide variation in the shape of the auricle.
- Almost any minor auricular defect may occasionally be found as a usual feature in a particular family.
- Minor defects of the auricles may serve as indicators of a specific pattern of congenital anomalies.
- For example, the auricles are often abnormal in shape and low-set in infants with chromosomal syndromes such as trisomy 18 and in infants affected by maternal ingestion of certain drugs (e.g., trimethadione).

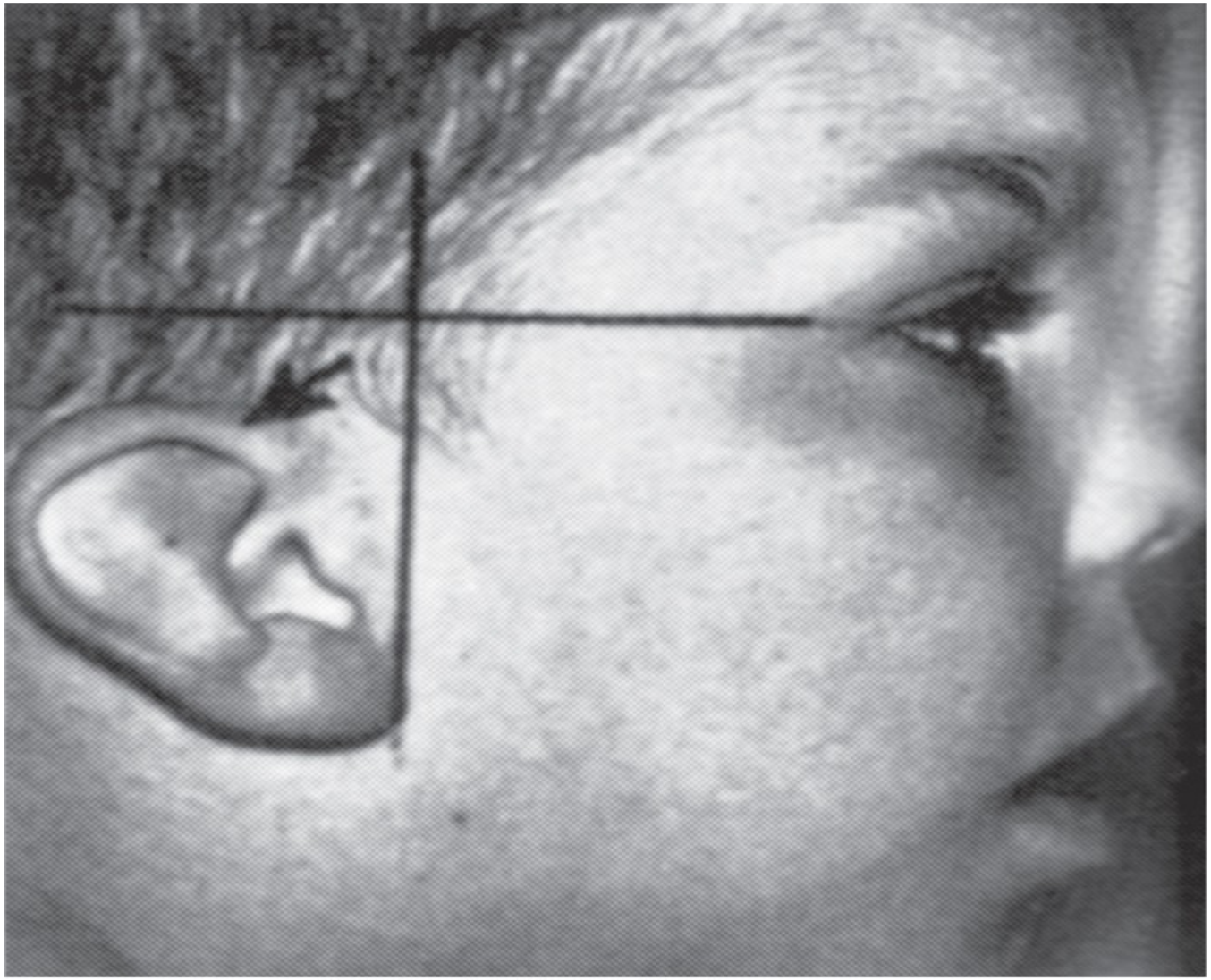

Moore et al: The Developing Human, 9e.
Copyright © 2013 by Saunders, an imprint of Elsevier Inc.

Low-set slanted ear. This designation is made when the margin of the auricle or helix (*arrow*) meets the cranium at a level inferior to the horizontal plane through the corner of the eye.

Absence of the Auricle

- Anotia (absence of the auricle) is rare but is commonly associated with the first pharyngeal arch syndrome.
- **Anotia** results from failure of mesenchymal proliferation.

Auricular Appendages

- Auricular appendages (skin tags) are common and may result from the development of accessory auricular hillocks.
- The appendages usually appear anterior to the auricle, more often unilaterally than bilaterally.
- The appendages, often with narrow pedicles, consist of skin but may contain some cartilage.

FIGURE 18–21 A child with a preauricular tag or

Moore et al: The Developing Human, 9e.
Copyright © 2013 by Saunders, an imprint of Elsevier Inc.

Microtia

- Microtia (a small or rudimentary auricle) results from suppressed mesenchymal proliferation
- This defect often serves as an indicator of associated birth defects, such as an atresia of the external acoustic meatus (80% of cases) and middle ear anomalies.
- The cause can be both genetic and environmental.

Moore et al: The Developing Human, 9e.
Copyright © 2013 by Saunders, an imprint of Elsevier Inc.

- **Preauricular Sinuses and Fistulas**
- Pit-like cutaneous depressions or shallow sinuses are occasionally located in a triangular area anterior to the auricle.
- The sinuses are usually narrow tubes or shallow pits that have pinpoint external openings.
- Some sinuses contain a vestigial cartilaginous mass.
- **Preauricular sinuses** may be associated with internal anomalies, such as deafness and kidney malformations.
- The embryologic basis of auricular sinuses is uncertain but it may relate to incomplete fusion of the auricular hillocks or to abnormal mesenchymal proliferation and defective closure of the dorsal part of the first pharyngeal groove.

- Other auricular sinuses appear to represent ectodermal folds that are sequestered during formation of the auricle.
- Bilateral preauricular sinuses are typically familial.
- The majority of sinuses are asymptomatic and have only minor cosmetic importance; however, they can become infected.
- **Auricular fistulas** (narrow canals) connecting the preauricular skin with the tympanic cavity or the tonsillar fossa are extremely rare.

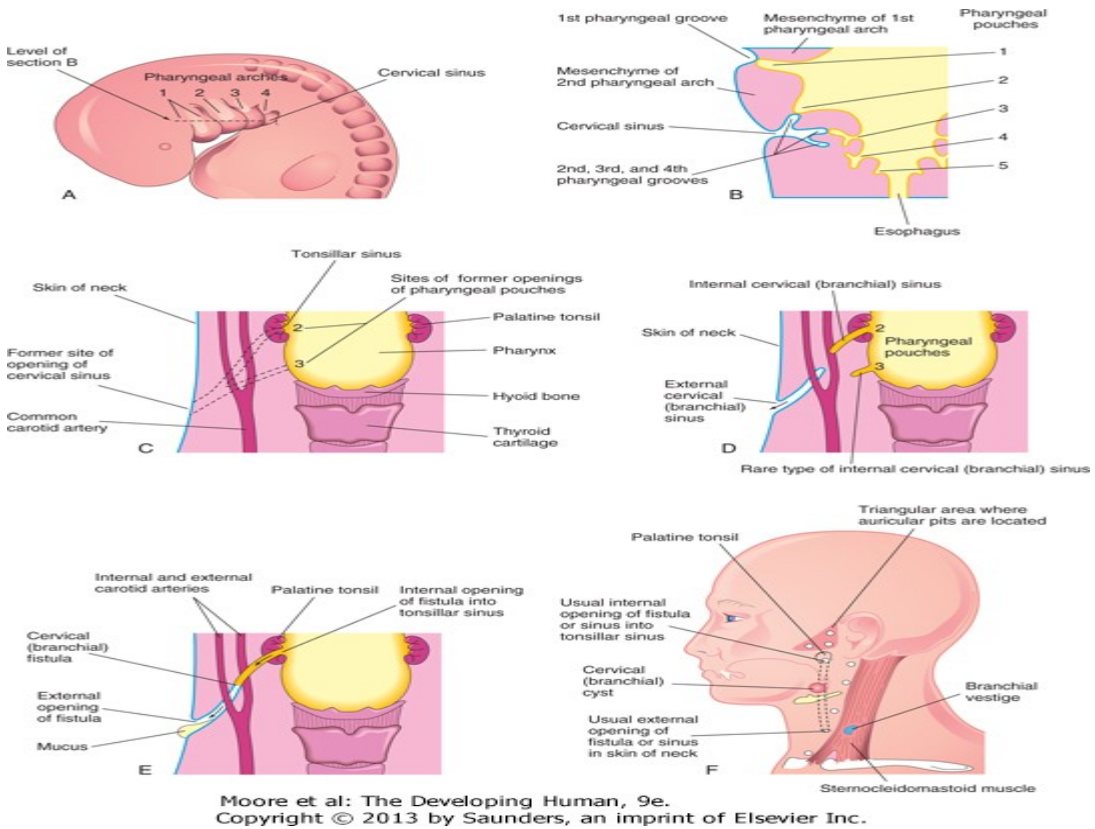

A, Lateral view of the head, neck, and thoracic regions of a 5-week embryo showing the cervical sinus that is normally present at this stage. **B,** Horizontal section of the embryo, at the level shown in **A**, illustrating the relationship of the cervical sinus to the pharyngeal arches and pouches. **C,** Diagrammatic sketch of the adult pharyngeal and neck regions indicating the former sites of openings of the cervical sinus and pharyngeal pouches. The *broken lines* indicate possible courses of cervical fistulas. **D,** Similar sketch showing the embryologic basis of various types of cervical sinus. **E,** Drawing of a cervical fistula resulting from persistence of parts of the second pharyngeal groove and second pharyngeal pouch. **F,** Sketch showing possible sites of cervical cysts and the openings of cervical sinuses and fistulas.

Moore et al: The Developing Human, 9e.
Copyright © 2013 by Saunders, an imprint of Elsevier Inc.

A child with an auricular fistula relating to the first pharyngeal arch. Note the external orifice of the fistula below the auricle and the upward direction of the catheter (in sinus tract) toward the external acoustic meatus.

Atresia of External Acoustic Meatus

- Atresia (blockage) of this canal results from failure of the meatal plug to canalize .
- Usually the deep part of the meatus is open, but the superficial part is blocked by bone or fibrous tissue.
- Most cases are associated with the *first arch syndrome*.
- Often abnormal development of both the first and second pharyngeal arches is involved.
- The auricle is also severely affected and defects of the middle and/or internal ear are sometimes present.
- Atresia of the external acoustic meatus can occur bilaterally or unilaterally and usually results from autosomal dominant inheritance.

- **Absence of External Acoustic Meatus**
- Absence of the external acoustic meatus is rare; usually the auricle is normal.
- This defect results from failure of inward expansion of the first pharyngeal groove and failure of the meatal plug to disappear.
- **Congenital Cholesteatoma**
- This is a fragment of keratinized epithelial cells that is retained after birth.
- The "rest" appears as a white cyst-like structure medial to and behind the tympanic membrane.
- It may be that the rest consists of cells from the meatal plug that was displaced during its canalization.
- It has been suggested that congenital cholesteatoma may originate from an epidermoid formation that normally involutes by 33 weeks gestation.
- Choleseatomas can exhibit growth and invasion of neighboring bone.

Moore et al: The Developing Human, 9e.
Copyright © 2013 by Saunders, an imprint of Elsevier Inc.

Copyrighted © by Dr. Mohamed El-Rouby 1998-2012

a- Large ears.
b- Protruding ears.
c- Lop ear, Cupped ear or Constricted ear (when the seems to fold down and forward).
d- Shell ear (when the curve in the outer rim, as well as the natural folds and creases, are missing).
e- Stahl ear or Spock's ear (pointed outer rim).
f- Cryptotia (Absence of depression between ear and head in back of the ear).
g- Micotia or anotia (Small or Absence of ear with or without external ear opening) 3 grades.
h- Ear lobes with large creases and wrinkles (old age).
i- Accessory lobe (Skin tags in cheeks with or without cartilage).

Clinical Vignette

- A pediatrician is asked to examine a young boy who has arrived from a country with poor access to medical care. The boy has low-set, misshapen ears, an underslung lower jaw, and a severe hearing deficit. The boy's teeth are also poorly aligned.
  - What is the common denominator for this set of conditions?

THANK YOU